

Radiofrequency assisted hemiglossectomy and neck dissection for cancer treatment of the mobile tongue

By Francesco Grazioli, MD (head of ENT department), Cesare Bartolomeo Neglia, MD (ENT consultant), Silvia Rezzonico, MD (ENT consultant), Gennarino De Thomasis, MD (ENT consultant) and Raffaele Manzo, MD (ENT consultant). ENT Department, Saronno (VA), Italy

To date several surgical techniques (laser, conventional electrosurgery, harmonic scalpel, cold dissection) are employed to perform transoral partial tongue resection and neck dissection for the treatment of mobile tongue cancer. The introduction of radiofrequency technology provides in this field of application a fast and easy-to-use method of dissection and coagulation, minimizing carbonization and thermal spread. Thus, it may significantly improve pain and edema outcomes in patients affected by this pathology.

Introduction: In Europe surgery is considered the first choice treatment for T1 and T2 carcinoma of the mobile tongue. A transoral approach is generally preferable, with the exception of tumors widely infiltrating the floor of the mouth, thus requiring a transmandibular approach. Neck dissection is always indicated in the case of T2 lesions, while in the case of smaller tumors it should be performed only with clinically positive or suspicious nodes. Transoral partial glossectomy is generally performed by means of cold scalpel dissection, conventional monopolar electrosurgery or laser assisted surgery. Conventional electrosurgery and laser provide a quicker cut and a better hemostasis compared to cold scalpel, but they are generally associated with postoperative greater edema and pain. Also for neck dissection several techniques are available, including cold instruments, electrosurgery, harmonic scalpel dissection, or combined techniques. The real benefit of expensive instruments such as the harmonic scalpel in neck dissection is still controversial, while the conventional electrosurgery is generally considered dangerous close to the noble structures of the neck, like large vessels and the accessory nerve. Radiofrequency could represent a valid alternative in both transoral surgery of the mobile tongue and neck dissection, due to several advantages, including high precision dissection and excellent coagulation. Furthermore, radiofrequency works at much lower temperatures compared to conventional electrosurgery, resulting in reduced thermal spread, no carbonization and less postoperative edema and pain.

Patient: A 34 year old male patient affected by a cT2N0 squamocellular carcinoma of the mobile tongue, was referred to our department for surgical treatment in March 2012. The tumor appeared as a 3 cm long infiltrating-ulcerated lesion, limited to the right lateral margin of the tongue. A CT scan excluded any involvement of the tongue base, the mouth floor and mandibula. No suspicious nodes were found with CT and US scan. A transoral hemiglossectomy associated to selective monolateral neck dissection was planned. Since the patient was judged at risk of postoperative accidents because of comorbidity (a mild mental retardation, congenital severe deafness and obesity), a prophylactic tracheostomy was also scheduled.

Methods: For the whole procedure we have employed the CURIS® Radiofrequency Unit (Sutter Medizintechnik, Freiburg/Germany), combining a micro-dissection monopolar needle (REF 36 03 25) for cutting, and the Super-Gliss® non-stick bipolar forceps (REF 78 21 81SG) for coagulating. After induction of general anesthesia and oro-tracheal intubation, a tracheostomy was performed, by means of radiofrequency-assisted dissection. The monopolar needle was used for skin incision, soft-tissue pre-tracheal dissection, and cutting the anterior wall of the trachea. The procedure

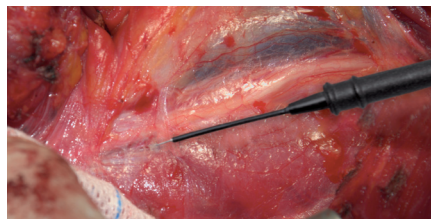


Fig. 1: Dissection of the perijugular connective tissue by means of CURIS® Radiofrequency Unit (Sutter Medizintechnik GmbH) using monopolar micro-dissection needle (REF 36 03 25).

was quick and there was no bleeding. No carbonization of tissues was observed. Afterwards, a selective neck dissection including I, II, III and IV neck levels, was executed. Radiofrequency-assisted dissection produced clean and sharp results, even close to the internal jugular vein and accessory nerve. "CUT1" monopolar mode on the unit was found to be an optimal setting providing a precise micro-dissection, at an intensity of 20-35 watts depending on tissue impedance. Lateral damage appeared to be very low, compared to conventional electrosurgery. For coagulating, the SuperGliss® non-stick bipolar forceps produced very efficient and comfortable results because the tips remained clean and perfectly working for the whole time. Finally, the transoral hemiglossectomy was performed, using the CURIS® Radiofrequency Unit setting the power to 20 watts in combination with a

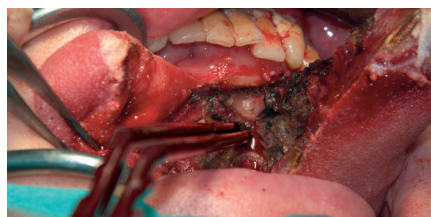


Fig. 2: Radiofrequency assisted transoral hemiglossectomy performed. Use of monopolar micro-dissection needle for cutting and SuperGliss® non-stick bipolar forceps (REF 78 21 81SG) for coagulating.

micro-dissection needle. This allowed a sharp dissection with minimum effort and low bleeding. After the resection, a primary resorbable suture was used to close the tongue wound.



Fig. 3: SuperGliss® non-stick, bipolar forceps (REF 78 21 81SG)

Postoperatively no complication was observed and wound healing occurred without delays. The patient complained of moderate pain in his mouth, no pain on the neck. Absolutely no edema was observed in the tongue. The patient started to eat two days postoperatively. The tracheostomy was closed five days postoperatively. The suture in the neck wound was removed eight days postoperatively.



Fig. 4: CURIS® RF unit (Sutter, Germany)

Conclusion: In our experience the CURIS® Radiofrequency Unit is a very useful instrument for both transoral surgery, neck dissection and tracheostomy, capable of combining the advantages of a sharp, dry and quick dissection with minimal lateral damage and carbonization; conclusively, it reduces postoperative pain and provides excellent edema outcomes.

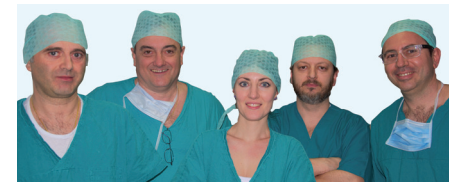

Fig. 5: From left: Dr. De Thomasis, Dr. Grazioli, Dr. Rezzonico, Dr. Manzo, Dr. Neglia

Correspondence: Dr. Francesco Grazioli, MD Chief of ENT Department, Piazza Borella 1, 20147 Saronno (VA), Italy, E-mail: fgrazioli@aobusto.it, Tel. +39 029613442

References: 1. Lydiatt DD, Robbins KT, Byers RM, Wolf PF. Treatment of stage I and II oral tongue cancer. *Head Neck.* Jul-Aug 1993;15(4):308-12. 2. Houck JR, Medina JE. Management of cervical lymph nodes in squamous carcinomas of the head and neck. *Semin Surg Oncol.* May-Jun 1995;11(3):228-39. [Medline]. 3. De Campora E., Marzetti F., *La chirurgia oncologica della testa e del collo.* 2 ed. Elsevier, 2006

Featured Product

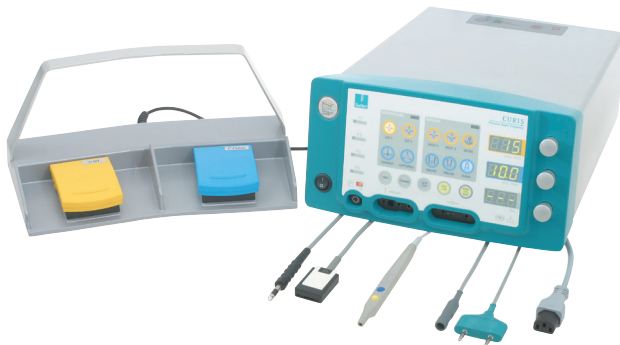

360325 – ARROWtip™ electrode

Qty.	REF	Description
2	360325	ARROWtip™ electrode, straight, Ø 2.4 mm, working length 30 mm

782181SG – SuperGliss® non-stick

Qty.	REF	Description
1	782181SG	SuperGliss® non-stick bipolar forceps, 1.0 mm tip, bayonet, working length 85 mm



870010 – CURIS® basic set with single-use patient plates

Qty.	REF	Description	Unit settings / Other accessories
1	360100-01	CURIS® radiofrequency generator (incl. main cord, user's manual and test protocol)	CURIS®
1	360110	Footswitch two pedals for CURIS® (cut & coag), 4 m cable	Arrowtip™ electrode: Monopolar CUT 1
1	370154L	Bipolar cable for CURIS®, length 3 m	Power adjustment: 20-35 watts
1	360704	Monopolar handpiece (pencil) cut & coag, shaft 2.4 mm, cable 3 m	Forceps: Bipolar PRECISE
1	360238	Cable for single use patient plates, length 3 m	Power adjustment: 20 watts
1 (x50)	360222	Safety patient plates, single use, packing 5 x 10 pcs. (not shown)	Optional: Rubber patient plate (REF: 360226)



SUTTER MEDIZINTECHNIK GMBH

TULLASTRASSE 87 · 79108 FREIBURG / GERMANY · TEL. +49 (0)761 51551-0 · FAX +49 (0)761 51551-30
WWW.SUTTER-MED.COM · WWW.SUTTER-MED.DE · E-MAIL : INFO@SUTTER-MED.DE