

# Calvian endo-pen® – New Non-Stick Coagulation Forceps for Endoscopic Endonasal Transsphenoidal Surgery to Remove Sellar Pathologies

By Rüdiger Gerlach, MD (Department of Neurosurgery), Gerafl Kellner, MD (Department of ENT Surgery) and Steffen Rosahl, MD (Department of Neurosurgery), HELIOS Klinikum GmbH Erfurt, Germany



Fig. 1: Calvian endo-pen® (REF 700950)

**Introduction:** Endoscopic endonasal transsphenoidal surgical procedures have gained wide acceptance for the treatment of lesions located at the central skull base (1;2). Various approaches have been described and performed at different degrees of invasiveness depending on the pathological site targeted. In many centers surgery is performed by interdisciplinary teams of ENT surgeons and neurosurgeons working together. The approach may be via one or both nostrils. Many dedicated surgical instruments have been introduced to cover all the requirements of the endoscopic approach and provide visibility during the intervention (3). Especially for less invasive surgical procedures via one nostril the need for thin and versatile instruments is a must. We have described the technical aspects of endoscopic surgical procedures as an interdisciplinary, minimally invasive approach to remove sellar pathologies e.g. pituitary adenomas. In addition to the surgical aspect we were able to assess the handling and the usability of new non-stick bipolar forceps with dedicated properties for minimally invasive endonasal surgery. These coagulation forceps are designed to fulfill all the requirements for endoscopic endonasal transsphenoidal surgery. The instrument is long and straight with slightly angled jaws, which can be closed by compression of the handpiece (Fig. 1).

## Surgical approach and patients treated:

For surgery the patient was in supine position while the upper part of the body was slightly elevated. The patient's head was fixated in a Mayfield clamp for the purpose of frameless neuronavigation. CT data was supplied for co-referentiation and neuronavigation. A uni-nostril approach was always used after endoscopic visualisation of both nostrils. The ENT surgeon began the surgery with neurosurgical assistance: The standard approach included lateralisation of the middle turbinate, dissection of a nasoseptal mucosa flap pediculated on the sphenopalatine artery and resection of the posterior part of the nasal septum. An anterior sphenoidectomy was performed in most cases with a diamond drill (4mm). No ethmoid bone was resected for standard approaches. After anterior sphenoidectomy, intrasphenoid septae were resected and

the mucosa was stripped off. In all cases carotid prominence and the optocarotid recess were used as landmarks for the opening of the sellar floor. The sellar floor was opened as wide as possible. After removal of the bone of the sellar floor coagulation may be difficult with conventional bayonet shaped instruments used for microscopic surgical procedures. For pure endoscopic procedures long, straight instruments are more suitable to be maneuvered through the nose. The tip of the instrument can be visualized with the endoscope while passing through the nostril and sphenoid sinus.

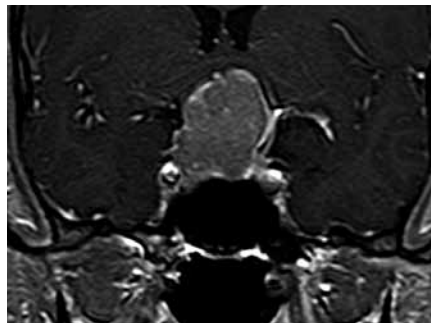


Fig. 2a

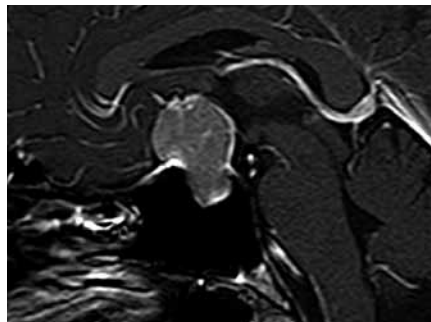


Fig. 2b

**Figs. 2a, 2b: preoperative contrast enhanced MRI in a) coronal and b) sagittal plane of a large intra and suprasellar growing pituitary adenoma with compression of the optic chiasma.**

We used the bipolar forceps in a consecutive series of 33 patients during the past 12 months. Most patients harbored pituitary adenomas (n=29). However, a few rare pathologies like pituitary abscess (n=2), a chordoma and a granuloma were also encountered. Figure 2 shows a typically large pituitary adenoma, which could be resected via one nostril.

**Results:** The Calvian endo-pen® bipolar forceps were used in all cases without

any difficulties. No complications attributable to the use of these bipolar forceps occurred during surgery. No complications occurred post-operatively. The general handling of the Calvian endo-

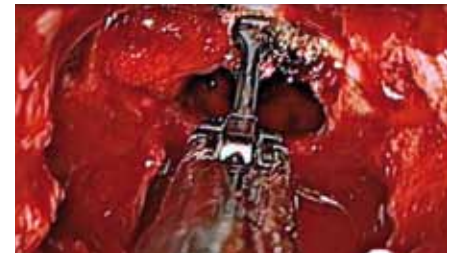

Fig. 3: bipolar coagulation of small vessels at the dural edges with Calvian endo-pen® (REF 700950)

pen® bipolar forceps is very comfortable and coagulation at the tip of the forceps very effective (Fig. 3). The hand-grips are made of soft rubber and rest nicely in one's hand like a pen. The compression of small springs underneath the handpieces allows the closing of the tip and self-adjusted reopening if pressure is slightly released. Tissue can be grasped and held while coagulation is performed with the small jaws at the angled tip. Although the tip has a fixed angle, the forceps may be rotated in the surgeon's hand to access the bleeding site. Especially the coagulation of oozing from the dural edges or bleeding from the intracavernous sinuses can be managed instantly.

**Conclusion:** The Calvian endo-pen® coagulation forceps are a highly effective means of coagulation and can be safely used for minimally invasive endoscopic endonasal transsphenoidal surgery.



**Rüdiger Gerlach, MD** (Department of Neurosurgery); **Gerafl Kellner, MD** (Department of ENT Surgery); **Steffen Rosahl, MD** (Department of Neurosurgery)

**Correspondence:** Rüdiger Gerlach, Gerafl Kellner, Steffen Rosahl, HELIOS Klinikum GmbH Erfurt, Nordhäuser Str. 74, 99094 Erfurt

**References:** 1. Paluzzi A, Gardner P, Fernandez-Miranda JC and Snyderman C: The expanding role of endoscopic skull base surgery. *Br J Neurosurg* 2012. 2. Schwartz TH, Fraser JF, Brown S, Tabae A, Kacker A, and Anand VK: Endoscopic cranial base surgery: classification of operative approaches. *Neurosurgery* 62:991-1002, 2008. 3. Snyderman CH, Carrau RL, Prevedello DM, Gardner P and Kassam AB: Technologic innovations in neuroendoscopic surgery. *Otolaryngol Clin North Am* 42:883-90, x, 2009.