

# Radiofrequency-Assisted Treatment of Rhinophyma

By Francesco Grazioli, Cesare Bartolomeo Neglia, Silvia Rezzonico, Gennarino De Thomasis and Raffaele Manzo. ENT Department, Saronno (VA), Italy

Surgical treatment of rhinophyma includes different traditional cold and hot techniques, but none of them is considered the gold standard for managing intraoperative bleeding and final scar results. New radiofrequency-assisted surgical units working at lower temperatures compared to electrocautery or laser have proven to be advantageous for this clinical application: Thermal damage spread to soft tissues and cartilage is considered a critical aspect in order to determine the final cosmetic results.



Fig. 1: Loop electrode (REF: 36 08 12)

**Introduction:** Representing the most significant clinical expression of acne rosacea, rhinophyma is characterized by the progressive thickening of skin of the lower third of the nose and the growth of typically hypertrophic irregular skin nodules, which are often aesthetically disabling. To date a number of surgical techniques have been employed in the management of rhinophyma, such as cold dissection with a traditional scalpel, electrocautery and laser-assisted surgery. Cold dissection generally causes major intraoperative bleeding due to rich local vascularization.

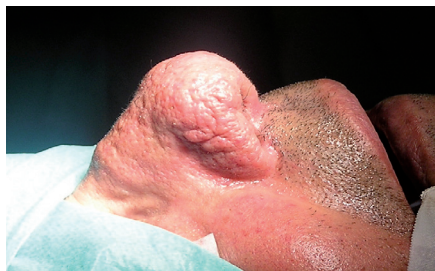

Fig. 2: Patient with rhinophyma

Electrocautery and laser surgery, by way of contrast, provide good hemostasis, but tend to be associated with greater pain compared to cold-dissection methods and have a significant risk of thermal cartilage damage resulting in unsatisfactory scars. The introduction of radiofrequency surgical units has provided a versatile and very maneuverable surgical technique, useful in several clinical procedures, able to supply optimal hemostasis and simultaneously reduce thermal spread.

**Case description:** In November 2012, a 58 years old patient afflicted by aesthetically disabling rhinophyma underwent surgical treatment of rhinophyma at our hospital. Operation was performed under general anesthesia. For resection of hypertrophic skin nodules the CURIS® radiofrequency generator (Sutter Medizin-technik, Freiburg/Germany), was used in monopolar CUT 1 mode at an intensity of 45 to 50 watts together with a triangle

shaped loop wire electrode (REF: 360812).

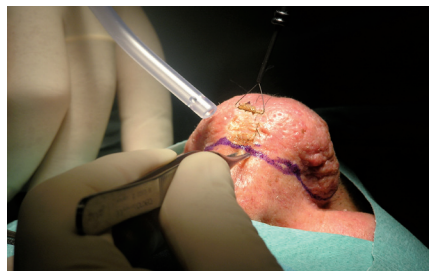


Fig. 3: Resection of superficial skin layers of the nose using a triangle shaped loop wire electrode

Superficial skin layers have been carefully resected and have produced a thickened uniformity comparable to normal skin around the lesion. A deep layer of skin was carefully preserved to avoid exposing underlying cartilage. During radiofrequency-assisted dissection the bleeding was negligible, and perfect hemostasis was easily obtained by means of the CURIS® radiofrequency generator using monopolar coagulation in CONTACT mode in a range of 20 to 24 watts together with a ball shaped electrode (REF: 360817).

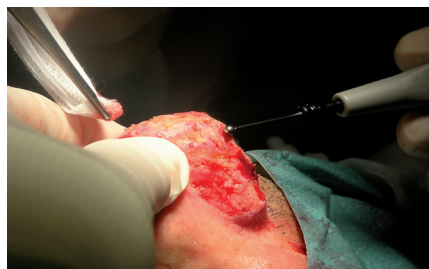

Fig. 4: Final hemostasis obtained by means of a ball shaped electrode

The entire procedure lasted around twenty minutes. The patient could be discharged after six hours of observation. After surgical intervention the patient underwent outpatient medications for two months twice a week. These consisted in the disinfection and application of fat ointments until complete wound repair was achieved. The patient did not complain of any significant postoperative pain, and no skin infection signs were observed.

Once re-epithelization was completed, the aesthetic result was judged to be optimal, and the patient was fully satisfied.

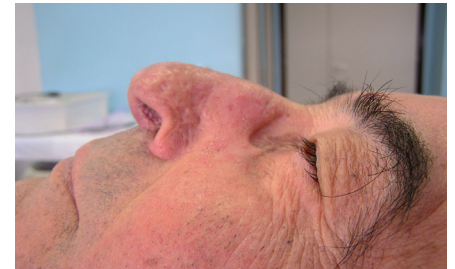

Fig. 5: Patient two months postoperatively

**Conclusion:** In our opinion, radiofrequency surgery is an ideal method for the treatment of rhinophyma. The most important benefit is represented by the feature of hemostasis, comparable to hot techniques such as electrocautery and



Fig. 6: CURIS® RF unit (Sutter, Germany)

the laser. Since radiofrequency works at lower temperatures compared with the hot techniques, thermal damage is insignificant, resulting in a low level of pain, fast wound repair and good scar results.



Fig. 7: From left: Dr. Manzo, Dr. Rezzonico, Dr. Neglia, Dr. Grazioli, Dr. De Thomasis, ENT Department, Saronno (VA), Italy

**Correspondence:** Dr. Francesco Grazioli, MD Chief of ENT Department, Piazza Borella 1, 20147 Saronno (VA), Italy. E-mail: fgrazioli@aobusto.it, Tel. +39 029613442

**References:** 1. Husein-ElAhmed H, Armijo-Lozano R. Management of severe rhinophyma with sculpting surgical decortication. *Aesthetic Plast Surg.* June 2013; Volume 37: pages 572-575 2. Sadick H, Goepel B, Bersch C, Goessler U, Hoermann K, Riedel F., Rhinophyma: diagnosis and treatment options for a disfiguring tumor of the nose. *Ann Plast Surg.* July 2008; Volume 61:114-120 3. Tahery J, Zakaria R, Natt RS, Diode laser treatment of rhinophyma. *Clinical Otolaryngology* October 2010; Volume 35: pages 442-444

## Featured Product



### 360812 – Loop electrodes

Qty.	REF	Description
5	360812	Loop electrode, total length 57 mm, 9.0 mm



### 360817 – Ball electrodes

Qty.	REF	Description
5	360817	Ball electrode, total length 60 mm, Ø 3.0 mm



### 870010 – CURIS® basic set with single-use patient plates

Qty.	REF	Description	Unit settings / Other accessories
1	360100-01	CURIS® radiofrequency generator (incl. main cord, user manual and test protocol)	CURIS®
1	360110	Footswitch two pedals for CURIS® (cut & coag), 4 m cable	Loop electrode: Monopolar CUT 1
1	370154L	Bipolar cable for CURIS®, length 3 m	Power adjustment: 45 to 50 watts
1	360704	Monopolar handpiece (pencil) cut & coag, shaft 2.4 mm, cable 3 m	Ball electrode: Monopolar CONTACT Coag
1	360238	Cable for single use patient plates, length 3 m	Power adjustment: 20 to 24 watts
1 (x50)	360222	Safety patient plates, single use, packing 5 x 10 pcs. (not shown)	



SUTTER MEDIZINTECHNIK GMBH

TULLASTRASSE 87 · 79108 FREIBURG / GERMANY · TEL. +49 (0)761 51551-0 · FAX +49 (0)761 51551-30  
WWW.SUTTER-MED.COM · WWW.SUTTER-MED.DE · E-MAIL : INFO@SUTTER-MED.DE