

Radiofrequency (RF) Surgery of the Posterior Pillars with a New Bipolar Probe

By Andrei Marinescu, MD, ENT Consultant, Winnenden, Germany; A. Neagos, MD, ENT Consultant Tg. Mures, Romania; C.-A. Hartmann, MD, Pathologist, Bergisch Gladbach, Germany

Many patients suffering from snoring and mild sleep apnea syndrome show deep-drawn posterior pillars with excess mucosal tissue ("webbing"). Resection of excess tissue of the posterior pillars and, where indicated, partial resection of the uvula are effective treatment options. However, they are not practical for an office setting due to the associated bleeding. To address webbing in an office-based setting, we have designed a bipolar probe (Fig. 1) for effective shrinkage of these structures without the need to actually cut.

Introduction: In an office-based study the efficacy of a new bipolar RF probe for posterior pillar reduction was evaluated. Surgical technique and the probe design are based on anatomical, pathophysiological [1] and histological [2] findings and the author's previous publications [3, 4] on RF treatment for snoring.

Patients and method: Nineteen patients (17 male and 2 female, average age 50 years, average BMI 29.3) suffering from simple snoring with hypertrophic or hypotonic pillar webbing were examined. The tonsils, tongue and septum of all patients were normal. Six patients underwent RF turbinate reduction prior to pillar treatment. Follow-up was performed 24 h, 48 h, one

Fig. 1: Bipolar webbing probe (Sutter, Germany) REF 70 04 89

Enlarged or lax pharyngeal pillars are suspected to be one possible cause of snoring. Minimally invasive RF treatment offers an attractive solution to this problem. The energy applied through a bipolar probe (Sutter, Germany, Fig. 1) leads to thermal damage, disintegration and shrinking. Subsequent cranial movement of the posterior pillars results in a widened isthmus of the fauces. This new approach makes cutting obsolete, thus preserving the palato-glossus muscle as well as the anterior pillars.

Surgical technique: Local anaesthetic spray (tetracaine) is administered while the patient is sitting. Four (2 to 3 ml) injections of xylocaine 1% with adrenaline 1:200.000 are placed along the anterior edge of the velum. For treatment each posterior pillar is divided in two or, if wider, three parts where the probe is inserted (Fig. 2). Thin and lax pillars tend to resist needle pressure. It may take a few attempts to insert the probe. To ensure correct placement, visual verification is advisable. Each site is treated for about 4 to 5 seconds with 9 watts in the RaVoR™ mode of the CURIS® (Sutter, Germany) (BM-780 II: precise, power "2"). A certain discolouring or minor necrosis of the tissue may be expected and will contribute to the desired effect.

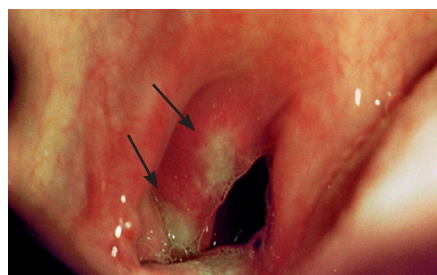


Fig. 2: Pillar immediately after RF treatment

week, two weeks and one month post-operatively. Between the second and the fourth month after surgery telephone interviews were conducted. On eight patients, the procedure was repeated after one month. On five patients, RF treatment of the soft palate was performed, in two cases together with pillar treatment. One patient underwent partial resection of the uvula. Histological examinations of the resected uvula tissue and biopsy of a treated pillar helped to evaluate the effects (Fig. 3).

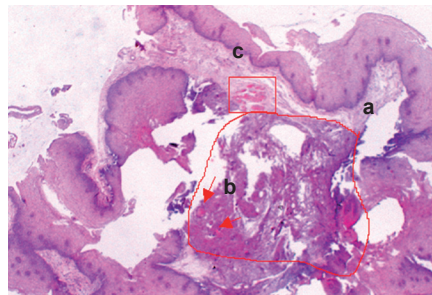


Fig. 3: Histology of the pillar: Coagulation and necrosis (a), thrombosis (b), atrophic muscle (c)

Results and Conclusion: All patients reported a reduction of the snoring volume or intensity. Sixteen patients felt a relief in the throat and reported better oral respiration eight days after the first session. Enlargement of the palatopharyngeal space could be observed (Fig. 5). During the first week after the intervention a generally mild oedema and manageable odynophagia were observed. Only the partial resection of the uvula caused transient difficulties in swallowing for the patient. The preliminary results suggest that the surgical method presented here is effective and well tolerated for short and medi-



Fig. 4: CURIS® RF unit (Sutter, Germany)

um-term treatment of habitual snoring. In particular as an addition to multi-level surgery it may be indicated and justified. Free nasal airflow is a precondition. A long uvula should always be shortened.

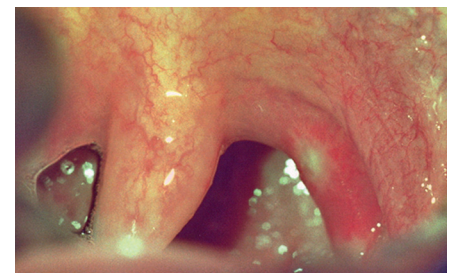

Fig. 5: Retracted pillar one week post-operatively

For the posterior pillars alone two sessions may be required. It is noteworthy that there were no perioperative or postoperative complications and hardly any bleeding. This method is ideal for the office-based setting.



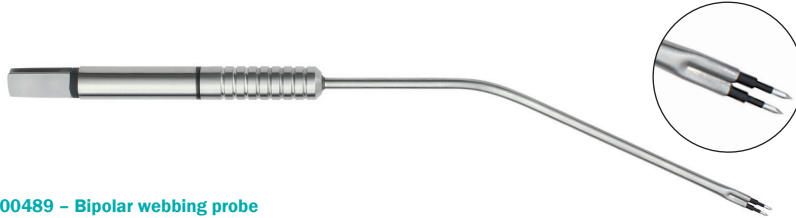Andrei Marinescu, MD
ENT Consultant
Winnenden, Germany

Correspondence: A. Marinescu, MD, ENT Consultant, Marktstr. 10, 71364 Winnenden, Germany. Tel. + 49 7195 2132, Fax +49 7195 179189, E-mail: a.marinescu@t-online.de

References: 1. Chevallier H, et. al. (1993) Anatomie du voile, incidences thérapeutiques dans le traitement du ronflement. Paris: Les monographies du cca Wagram: 8-32 2. Woodson BT, et. al. (1991) Histopathologic changes in snoring and obstructive sleep apnea syndrome. Laryngoscope 101: 1318-1323 3. Marinescu A (2008) Bipolar Radiofrequency Volume Reduction RaVoR™ with ORL Set for Treatment of Habitual Snoring. ENTNews Vol 17 No 1 March/April 08: 64 4. Marinescu A (2004) Bipolare Radiofrequenz-Volumenreduktion mit "ORL-Set" bei habituellen Rhonchus, Laryngo-Rhino-Otol 83:610-616

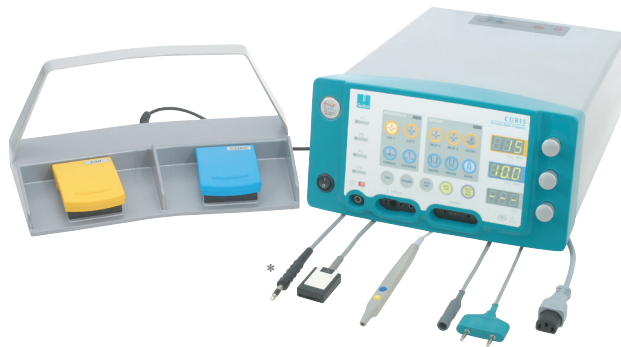Ordering Information

Featured Product



700489 – Bipolar webbing probe

Qty.	REF	Description
1	700489	Bipolar webbing probe, work length 120 mm, needle 2,5 mm



870010 – CURIS® basic set with single-use patient plates

Qty.	REF	Description
1	360100-01	CURIS® radiofrequency generator (incl. mains cord, user's manual and test protocol)
1	360110	Footswitch two pedals for CURIS® (cut & coag), 4 m cable
1	370154 L	Bipolar cable for CURIS®, length 3 m
1	360704	Monopolar handpiece (pencil) cut & coag, shaft 2.4 mm, cable 3 m
1	360236	Cable for single use patient plates, length 4.5 m
1 (x50)	360222	Safety patient plates, single use, packing 5 x 10 pcs. (not shown)

***Optional**

1	360226	Patient plate with cable, re-usable, length 4 m
---	--------	---



SUTTER MEDIZINTECHNIK GMBH

TULLASTRASSE 87 · 79108 FREIBURG / GERMANY · TEL. +49 (0)761 51551-0 · FAX +49 (0)761 51551-30
WWW.SUTTER-MED.COM · WWW.SUTTER-MED.DE · E-MAIL : INFO@SUTTER-MED.DE