

Resection of Squamous Cell Carcinoma of the Tongue Using Radiofrequency Surgery: A Case Report

By Clemens Heiser, MD & Andreas Knopf, MD; Department of Otorhinolaryngology, Head and Neck Surgery, Klinikum rechts der Isar, Technische Universität München

Introduction: Tumors of the tongue can be divided into benign, precancerous and, malignant lesions. Diagnosis is usually made after lesional biopsy. Most malignant tumors represent common head-and-neck squamous cell carcinoma with keratinizing, nonkeratinizing, anaplastic, basaloid-squamous, or adenoid cystic carcinomas. 95% of the malignant tumors of the tongue are well-differentiated squamous cell carcinomas. 75% of these carcinomas are located at the lateral border of the tongue and show superficial ulcerations. Therapeutic regimes may differ depending on local tumor expansion, metastatic spread, and histological subtype. Complete tumor resection with or without neck dissection and adjuvant radio- (chemo-) therapy usually represents first-line therapy.

For hemostasis non-stick bipolar forceps (REF 780175SG) were used (Fig. 4). Final histological examination revealed a totally extirpated tumor with a safety margin of one centimeter (Fig. 5).

effective tool for dissecting tumors under local anesthesia achieving a good combination of radicality and hemostasis.

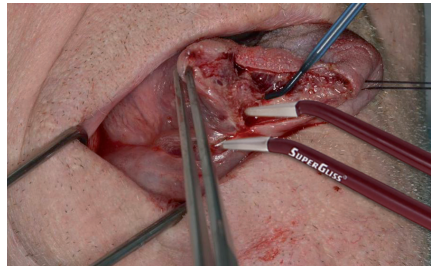


Fig. 4: Dissection of the tumor using a monopolar RF needle.

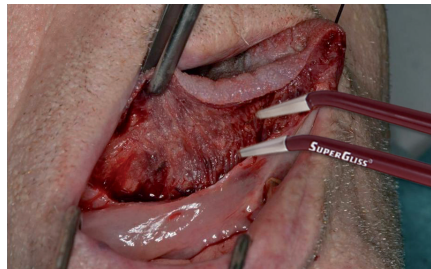


Fig. 5: Diffuse bleeding was staunched using bipolar forceps.

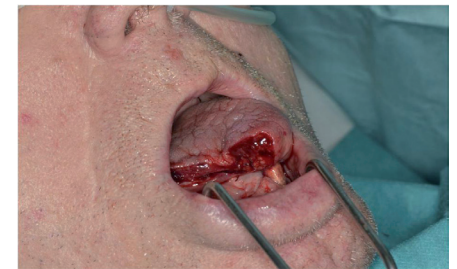

Fig. 6: Operative site after total tumor extirpation.

Conclusion: We consider radiofrequency surgery an effective tool in the surgical treatment of tongue carcinomas. Even under local anesthesia twitches of the tongue are rare. In contrast to laser-assisted or common monopolar surgery, radiofrequency provides a minimal coagulation area that facilitates a proper histological examination.



Fig. 1: ARROWtip™ electrode (REF 36 03 25)

Methods: A 75-year old male patient suffered from a painful ulcerous lesion at the lateral side of the tongue. Lesional biopsy revealed a keratinizing squamous cell carcinoma (Fig. 2).

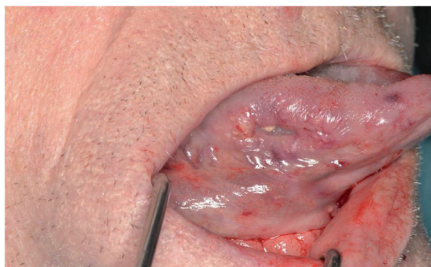


Fig. 2: Ulcerous lesion of the right side of the tongue.

Due to severe comorbidity, the patient underwent hemiglossectomy under local anesthesia. The excision was performed with the 4 MHz CURIS® Radiofrequency Generator (Sutter Medizintechnik GmbH, Freiburg/ Germany) using a monopolar RF needle (REF 360325).

Results: Sufficient local anesthesia was achieved by infiltrative application of lidocaine. The malignant lesion was totally extirpated with a safety margin of more than 1.0 centimeters. During surgery no twitches of the tongue occurred. A safe and also fast dissection was possible with a nearly bloodless situation. No postoperative recovery in the ICU was needed. Due to patient's comorbidity oral nutrition started one day after surgery.

Discussion: In carcinomas of the tongue, treatment regimes focus on complete tumor extirpation. The en-bloc tumor resection represents first-line surgery and prevents further seeding of tumor cells. Tumor surgery of the tongue aims to obtain a balance between radicality and functionality. Esthetic points need to be taken into consideration as well. For a carcinoma of the tongue different dissection options are available: One method is to use cold steel dissection. The disadvantage of this method is the bleeding and the twitches of the tongue under local anesthesia, which can occur. Another possibility is laser surgery. However, this should be done under general anesthesia as the patient should not move his body or even his tongue during surgery. Radiofrequency represents an



Dr. Clemens Heiser Klinikum rechts der Isar, München



Dr. Andreas Knopf Klinikum rechts der Isar, München

Correspondence:

Dr. Clemens Heiser, Department of Otorhinolaryngology, Head and Neck Surgery, Klinikum rechts der Isar, Technische Universität München, Ismaninger Str. 22, 81675 München, Germany. Phone: + 49 89 4140-2370, Fax: +49 4140-4853, Email: c.heiser@lrz.tum.de

References:

1. Basterra J, Fraix S, Alba JR, Zapater E. A new device for treating laryngeal carcinoma using microdissection electrodes. *Laryngoscope*. 2006 Dec;116 (12): 2232-4
2. Basterra J, Zapater E, Moreno R, Hernández R. Electrosurgical endoscopic cordectomy with microdissection electrodes. A comparative study with CO2 laser cordectomy. *J Laryngol Otol* 2006 Aug;120 (8): 661-664



Fig. 3: CURIS® RF unit (Sutter, Germany).

Featured Product

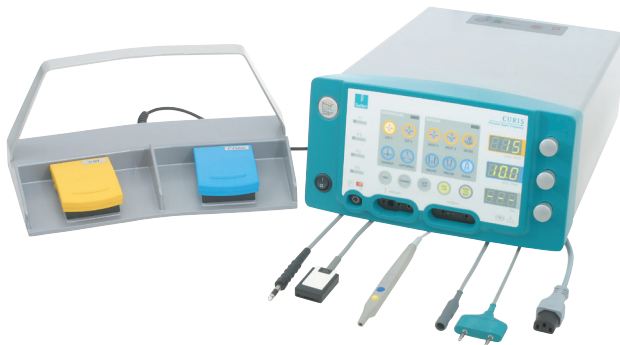

360325 – ARROWtip™ electrode

Qty.	REF	Description
2	360325	ARROWtip™ electrode, straight, Ø 2.4 mm, working length 30 mm

780175SG – SuperGliss® non-stick

Qty.	REF	Description
1	780175SG	SuperGliss® non-stick bipolar forceps, 1.0 mm tip, straight, working length 45 mm, total length 185 mm



870010 – CURIS® basic set with single-use patient plates

Qty.	REF	Description	Unit settings / Other accessories
1	360100-01	CURIS® radiofrequency generator (incl. main cord, user manual and test protocol)	CURIS®
1	360110	Footswitch two pedals for CURIS® (cut & coag), 4 m cable	ARROWtip™ electrode: Monopolar CUT 2
1	370154L	Bipolar cable for CURIS®, length 3 m	Power adjustment: 22 watts
1	360704	Monopolar handpiece (pencil) cut & coag, shaft 2.4 mm, cable 3 m	Forceps: BICUT 2 and PRECISE
1	360238	Cable for single use patient plates, length 3 m	Power adjustment: 25 to 30 watts
1 (x50)	360222	Safety patient plates, single use, packing 5 x 10 pcs. (not shown)	



SUTTER MEDIZINTECHNIK GMBH

TULLASTRASSE 87 · 79108 FREIBURG / GERMANY · TEL. +49 (0)761 51551-0 · FAX +49 (0)761 51551-30
WWW.SUTTER-MED.COM · WWW.SUTTER-MED.DE · E-MAIL : INFO@SUTTER-MED.DE