

Procedure Guidelines for bipolar Radiofrequency Volume Reduction (RaVoR™) of the Soft Palate

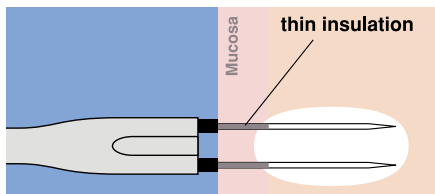


Fig. 1: Correctly placed RaVoR™ bipolar electrode. Complete insertion of the thin insulation protects the mucosa from surface lesions.

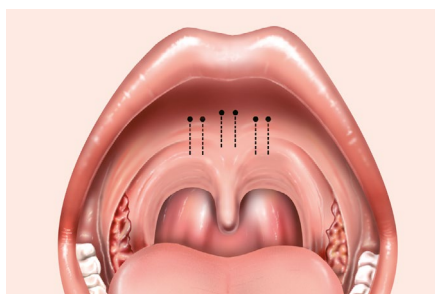


Fig. 2: Puncture sites for the application of radiofrequency energy in the soft palate with RaVoR™ bipolar electrode (REF: 70 04 95).

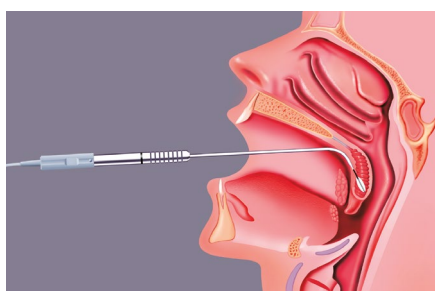


Fig. 3: Illustration showing the correct position of the RaVoR™ bipolar electrode in the middle of the soft palate tissue.

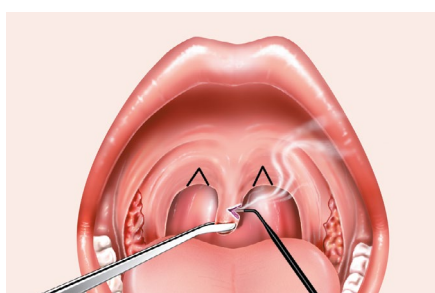


Fig. 4: Dissection of surplus uvula tissue and incision lines for the triangular excision of the posterior palatal pillars.

Indications and contraindications

Palatal snoring in connection with primary snoring or mild obstructive sleep apnea, which otherwise requires no separate treatment.

Patient preparation

The intervention is performed under local anesthesia on an outpatient basis. Preoperatively apply a surface anesthetic (e.g. lidocaine spray) and inject a local anesthetic together with a vasoconstrictor (e.g. lidocaine 2 % plus adrenaline 1:200 000) just behind the line between the stiff and the soft palate and at the base of the uvula (about 5 to 8 times in total). Verify that the insulation of both the monopolar and bipolar electrodes is intact before using them. Do not use defective or damaged instruments to avoid the risk of burns.

Intervention

Insert the RaVoR™ bipolar electrode (REF: 70 04 95) (Fig. 5) just behind the line between the stiff and the soft palate. Insert the electrode completely with its thin insulation layer (Fig 1). Administer the first puncture median and, depending on the anatomy, 1 or 2 applications laterally to the right and left (Fig. 2). Insert the needle into the middle of the soft palate tissue to avoid lesions of the oral and pharyngeal surfaces of the palate (Fig. 3). Visible changes in the mucosa are not likely. Stop applying energy if you observe a slight, white discoloring of the mucosa. In the case of a second session, choose neighboring puncture sites and do not insert the probe in the same place. If the uvula and the posterior palatal pillars have excess mucosa tissue (webbing), dissect the surplus mucosa with a cutting electrode (ARROWtip™ monopolar microdissection electrode REF: 36 03 42). Be careful to avoid lesions of the uvular muscles and the palatal pillars when cutting away excess mucosa tissue and making a triangular excision to remove surplus tissue of the posterior palatal pillar (Fig. 4).



Fig. 5: RaVoR™ bipolar electrode for the soft palate (REF: 70 04 95). Marking: a dot on the handpiece.



Fig. 6: ARROWtip™ monopolar microdissection electrode (REF: 36 03 42)


Postoperative treatment

Specific postoperative treatment is not required. If necessary, prescribe analgetics. The pain might be stronger if it had been necessary to dissect excess mucosa. Inform your patients that the therapeutic effect will occur with a delay. In the days following surgery, snoring symptoms may temporarily be more pronounced due to postoperative tissue swelling.

Settings for BM-780 II Radiofrequency Generator (REF: 36 00 80-01)

RaVoR™ bipolar electrode: Bipolar PRECISE
Power adjustment: 2, ⌚ 9 sec.

ARROWtip™ monopolar microdissection electrode: Monopolar CUT 2
Power adjustment: 2.5



Other accessories:

Bipolar cable (REF: 37 01 38 L), monopolar handpiece (REF: 36 02 18), cable (REF: 36 02 36) and single-use patient plate (REF: 36 02 22)

* Please consider that this information is not meant to serve as a detailed treatment guide. Always start with the lowest settings and adjust them accordingly.

Disclaimer: These procedure guidelines have been carefully researched and compiled with the help of specialist physicians. They are not meant to serve as a detailed treatment guide. They do not replace the user instructions for the medical devices used. Sutter accepts no liability for the treatment results beyond legal regulations.