

Procedure Guidelines for bipolar Radiofrequency Volume Reduction (RaVoR™) of the Nasal Turbinates

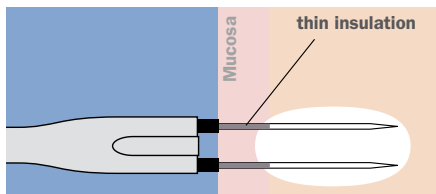


Fig. 1: Correctly placed RaVoR™ bipolar electrode. Complete insertion of the thin insulation protects the mucosa from surface lesions.

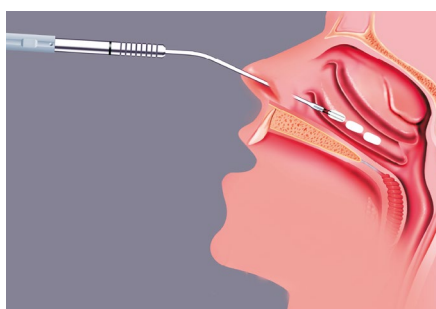


Fig. 2: Puncture sites for the application of radiofrequency energy of the inferior turbinate with RaVoR™ bipolar electrode REF: 70 04 62.

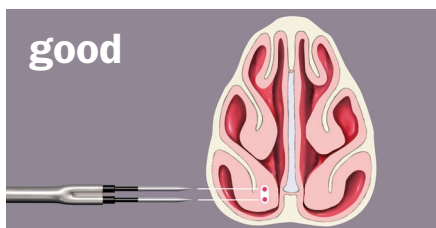


Fig. 3: Correct insertion in the middle of the nasal concha.

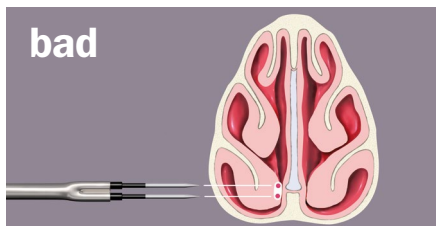


Fig. 4: Puncture too close to the nasal septum.

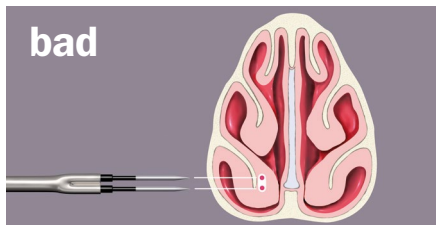


Fig. 5: Puncture too close to the bone of the nasal concha.

Disclaimer: These procedure guidelines have been carefully researched and compiled with the help of specialist physicians. They are not meant to serve as a detailed treatment guide. They do not replace the user instructions for the medical devices used. Sutter accepts no liability for the treatment results beyond legal regulations.

Indications and contraindications

Follow the general recommendations for surgery of the inferior turbinates. There are no contraindications for RF surgery.

Patient preparation

The intervention is performed under local anesthesia on an outpatient basis. Apply a surface anesthetic (e.g. insert a cotton strip soaked in lidocaine 4 % or use a spray, optionally with a vasoconstrictor such as xylometazoline, adrenaline). Inject 2 to 3 ml local anesthetic (e.g. lidocaine 2 %) into each of the inferior turbinates.

Verify that the insulation of the bipolar electrodes is intact before using them. Do not use defective or damaged instruments to avoid the risk of burns.

Intervention

Insert the RaVoR™ bipolar electrode (REF 70 04 62) completely with its thin insulation layer into the anterior head of the turbinate (medial surface) parallel to the bone (see figs. 3-5). Apply radiofrequency to the head of the turbinate. Repeat the procedure in the middle part of the turbinate and, if indicated, in the posterior third of the nasal turbinates (medial surface). To treat pronounced cases of hyperplasia of the anterior head of the turbinate a second puncture may be required. Visible changes in the mucosa are not likely. Stop applying energy if you observe a slight, white discoloring of the mucosa.




Fig. 5: RaVoR™ bipolar electrode for inferior turbinates (REF: 70 04 62)

Postoperative treatment

Specific postoperative treatment is not required. If necessary, give pain killers (paracetamol or diclofenac). Inform your patients that the therapeutic effect will occur with a delay. In the days following surgery, nose breathing may temporarily be more obstructed due to postoperative tissue swelling. If required, prescribe nasal spray that reduces swelling (e.g. xyloetazoline).

Settings for BM-780 II Radiofrequency Generator (REF: 36 00 80-01)

RaVoR™ bipolar electrode: Bipolar PRECISE
Power adjustment: 2, ⌚ 5-9 sec.



Other accessories:
Bipolar cable (REF: 37 01 38 L)

* Please consider that this information is not meant to serve as a detailed treatment guide. Always start with the lowest settings and adjust them accordingly.