

Combined Radiofrequency Volumetric Tissue Reduction and Outfracture of Hypertrophic Inferior Turbinates in the Treatment of Chronic Rhinitis: Short- and Long-Term Results

By Paraya Assanasen, Associate Professor, Bangkok, Thailand

Chronic Rhinitis (CR) is usually managed medically; yet, in spite of adequate medical managements, some patients find them ineffective. Radiofrequency volumetric tissue reduction (RaVoR™) of hypertrophic inferior turbinates (IT) is an effective way to treat patients with intractable nasal mucosal obstruction. However, it has no effect upon bony turbinate enlargement, and immediate nasal obstruction causes much discomfort for patients postoperatively. The aim of this study was to evaluate the effectiveness of combined RaVoR™ and outfracture of hypertrophic IT in patients with CR for the reduction of nasal obstruction and its long-term outcome.



Fig. 1: Bipolar "Binner" probe (Sutter, Germany) REF 70 04 62

Methods: From August 2007 to October 2009, seventy-three patients with CR who suffered from intractable nasal obstruction and did not respond to medical treatment were prospectively recruited to undergo combined RaVoR™ and outfracture

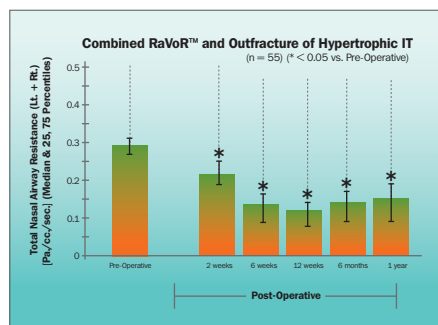


Fig. 2: Significantly decreased total nasal airway resistance

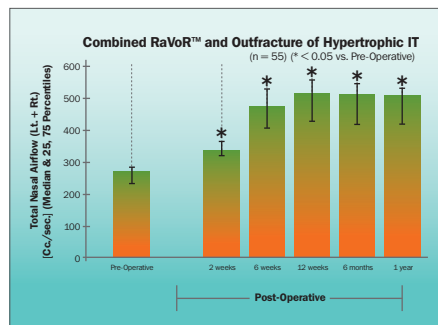


Fig. 3: Significantly increased total nasal airflow

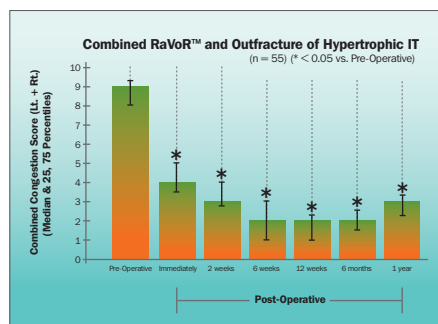


Fig. 4: Significantly decreased total nasal congestion score

of hypertrophic IT. The definition of CR included evidence of sneezing, itching, rhinorrhea, nasal obstruction for more than one month after exposure to any stimuli without skin testing. Intractable nasal obstruction was defined by the failure to medical treatment (steam inhalation, short-course systemic steroids, double-dose of intranasal steroids, oral decongestant) for at least one month. The operation was performed under local anesthesia. Cottonoids soaked with 1% xylocaine were packed along the inferior turbinates of both nasal cavities for five minutes, and 0.5% xylocaine with adrenaline 1:200,000 was injected into the turbinates.

RaVoR™ was performed with an impedance-controlled radiofrequency system (CURIS® or BM-780 II, Sutter Medizintechnik, Germany). Radiofrequency energy was applied submucosally to the anterior (3 lesions) and to the middle part (3 lesions) of the inferior turbinate (CURIS®: RaVoR™ AutoStop mode, 8 watts; BM-780 II: bipolar precise mode, intensity 2-3, 9-10 seconds). The outfracture of IT was then performed bilaterally. After the operation thin degradable nasal packing was placed along the inferior turbinates. Patients were under supervision in the recovery area for half an hour before there were discharged from the hospital. Home medication included oral antibiotics, non-sedating antihistamine, acetaminophen, and topical decongestants (0.05% oxymetazoline). The nasal congestion score (0-5) was recorded for each nostril before and immediately after surgery as well as 2 weeks, 6 weeks, 3 months, 6 months and 1 year after the operation. The nasal congestion score consisted of numeric scores ranging from 0 to 5:

- 0 = no congestion
- 1 = very mild congestion
- 2 = mild or slight congestion
- 3 = moderate congestion
- 4 = severe congestion
- 5 = very severe congestion

Total nasal airway resistance (TNAR) and total nasal airflow (TNA) were measured by



Fig. 5: CURIS® RF unit (Sutter, Germany)

active anterior rhinomanometry (ATMOS 300, Germany) before the surgery as well as 2 weeks, 6 weeks, 3 months, 6 months and 1 year after.

Results: Fifty-five patients completed the follow-up period of one year. Subjects consisted of 30 male and 25 female patients, with an age average of 29 years. The nasal congestion score improved significantly immediately after the operation ($p < 0.05$) and also 2 weeks, 6 weeks, 3 months, 6 months and 1 year after the operation ($p < 0.05$). The TNAR values had significantly decreased while the TNA had significantly increased at each follow-up postoperatively ($p < 0.05$) in comparison to the preoperative values.

Conclusion: Combined RaVoR™ and outfracture of hypertrophic IT is an effective treatment for nasal obstruction in CR and the result could be seen immediately and up to one year after the operation.




Paraya Assanasen
Associate Professor,
Mahidol University,
Bangkok, Thailand

Correspondence: Associate Professor, Rhinology and Allergy Division, Department of Otorhinolaryngology, Faculty of Medicine Siriraj Hospital, 2 Prannok Rd., Mahidol University, Bangkok, THAILAND 10700, Tel: (662) 02-419-9520, Fax: (662) 02-419-8044, E-Mail: paraya.assanasen@gmail.com


References: 1. Nease CJ, Kreml GA. Radiofrequency treatment of turbinate hypertrophy: a randomized, blinded, placebo-controlled clinical trial. *Otolaryngol Head Neck Surg* 2004;130:291-9. 2. Porter MW, Hales NW, Nease CJ, et al. Long-term results of inferior turbinate hypertrophy with radiofrequency treatment: a new standard of care? *Laryngoscope* 2006;116:554-7. 3. Banhiran W, Tantilipikorn P, Methetrairut C, et al. Quality of life in patients with chronic rhinitis after radiofrequency inferior turbinate reduction. *J Med Assoc Thai* 2010;93(8):950-60.

Featured Product



700462 – Bipolar needle electrode „Binner“

Qty.	REF	Description
1	700462	Bipolar needle electrode „Binner“ with protective insulation, work length 110 mm



870010 – CURIS® basic set with single-use patient plates

Qty.	REF	Description
1	360100-01	CURIS® radiofrequency generator (incl. mains cord, user's manual and test protocol)
1	360110	Footswitch two pedals for CURIS® (cut & coag), 4 m cable
1	370154L	Bipolar cable for CURIS®, length 3 m
1	360704	Monopolar handpiece (pencil) cut & coag, shaft 2.4 mm, cable 3 m
1	360238	Cable for single use patient plates, length 3 m
1 (x50)	360222	Safety patient plates, single use, packing 5 x 10 pcs. (not shown)

*Optional model

CURIS® basic set with re-usable patient plate (REF 870020)



SUTTER MEDIZINTECHNIK GMBH

TULLASTRASSE 87 · 79108 FREIBURG / GERMANY · TEL. +49 (0)761 51551-0 · FAX +49 (0)761 51551-30
WWW.SUTTER-MED.COM · WWW.SUTTER-MED.DE · E-MAIL : INFO@SUTTER-MED.DE