

# Radiofrequency reduction of inferior turbinates in patients with allergic and non-allergic rhinitis

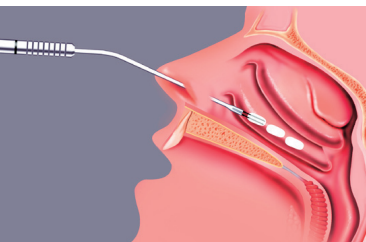
Dr. D. S. Deenadayal, Dr. B. Vyshanavi

**Introduction:** Chronic nasal obstruction is one of the most frequent complaints expressed by patients with allergic or non-allergic rhinitis. These patients are usually on long-term medical treatment with remission of symptoms followed by exacerbation. Surgery is a definitive option for such patients. There is no consensus as to which is the best treatment option for these patients. Although the surgical approach for such patients will usually be limited to the turbinates, our experience has shown that treatment of the turbinates is beneficial in conjunction with other surgical techniques. In our study, we used the method of impedance-controlled radiofrequency-assisted volumetric reduction of the inferior turbinates to treat these patients. Results have shown that, when using this minimally invasive method together with other surgical techniques, the outcomes of surgery for patients with allergic and non-allergic rhinitis can be improved.

**Materials and Methods:** A total of 1500 patients were included in our study. All of them underwent turbinate reduction with the CURIS® 4 MHz radiofrequency generator as well. The majority of the patients complained of nasal obstruction followed by nasal discharge, excessive sneezing, snoring, and hyposmia. Grading of the turbinate size was based on the chart shown below.

Grade 1	Inferior turbinate occupying 25% of the nasal cavity
Grade 2	Inferior turbinate occupying 50% of the nasal cavity
Grade 3	Inferior turbinate occupying 75% of the nasal cavity

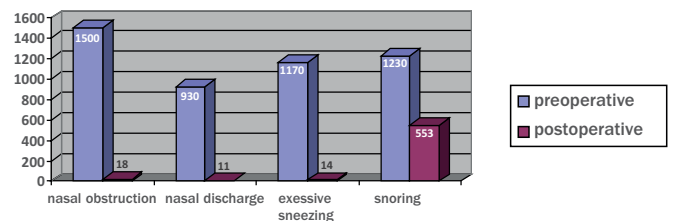
This equipment was introduced in our set-up three years ago. Patients undergoing turbinate reduction in addition to septoplasty and endoscopic sinus surgery were also included in our study. For most of the patients, the intervention was performed under general anesthesia. For a few patients who were treated for isolated turbinate reduction, only local anesthesia was used. After taking all the necessary sterile precautions, the turbinates were infiltrated with 2% xylocaine with 1:100000 adrenaline. The RaVoR™ bipolar electrode for inferior turbinate is introduced submucosally in the turbinate as shown in the picture below. It is inserted initially on the head of the inferior turbinate followed by the middle part and then the posterior aspect. The application of radiofrequency energy should stop as soon as you see a whitish discoloration of the inferior turbinate.



**Results:** The majority of patients experienced relief from the symptoms, in particular nasal obstruction. In addition, they also experienced relief from nasal discharge, excessive sneezing, snoring, and mouth breathing.

Improvement with regard to symptoms is shown in the graph above. No major complications were reported during the first two weeks. Almost all of the patients complained of crusting in the nose, which was managed by regular nasal toileting. A few patients also suffered from nosebleeds.

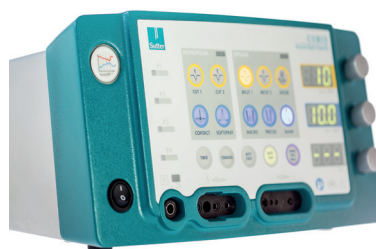Fig 1: Table comparing pre- and postoperative symptoms.




**Conclusion:** Reduction of the inferior turbinates is imperative for patients suffering from allergic and non-allergic rhinitis. RaVoR™ is a highly effective method with minimal complications and should be considered in the treatment of the inferior turbinates.



RaVoR™ bipolar electrode „Binner“ for inferior turbinate (REF: 70 04 62)



CURIS® 4 MHz radiofrequency generator (REF: 36 01 00-01)



**Dr. B. Vyshanavi**  
Aarti Clinic, 9-1-193, St. Mary's  
Road, Secunderabad-500 003

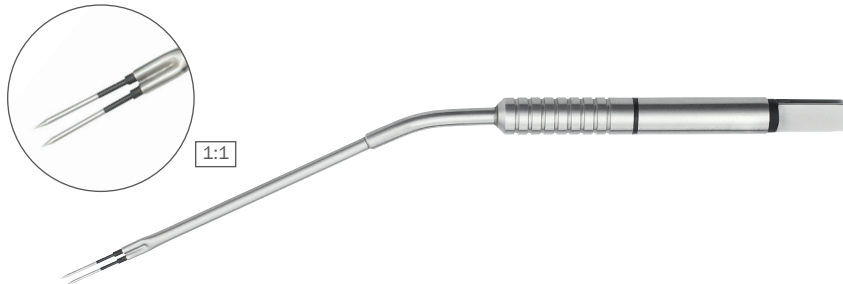


**Dr. D. S. Deenadayal**  
Aarti Clinic, 9-1-193, St. Mary's  
Road, Secunderabad-500 003

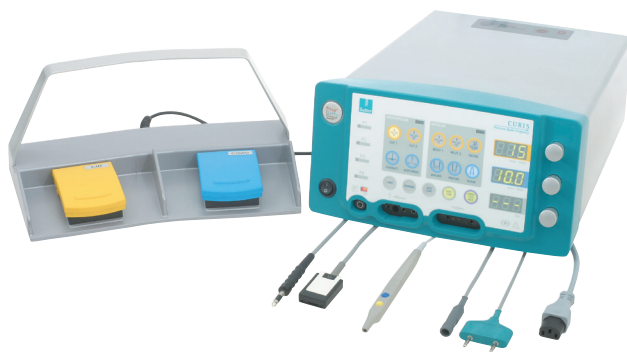**Correspondance:** Dr. D. S. Deenadayal, Dr. B. Vyshanavi

**References:** 1. Naclerio RM, Bachert C, Baraniuk J N. Pathophysiology of nasal congestion. *Int J Gen Med.* 2010;3:47-57. Available at: <http://www.ncbi.nlm.nih.gov/pubmed/20463823>. Accessed December 16, 2016. 2. Chhabra N, Houser S M. Surgical options for the allergic rhinitis patient. *Curr Opin Otolaryngol Head Neck Surg.* 2012;20(3):199-204. doi:10.1097/MO0.0b013e328352b821. 3. G. M. Bran (✉) S. Hünnebeck K., Hörmann B. A., Stuck, Department of Otorhinolaryngology, Head and Neck Surgery, University Hospital Mannheim, Heidelberg University, Theodor-Kutzer-Ufer 1-3, 68161 Mannheim, Germany E-Mail: [gregor.bran@web.de](mailto:gregor.bran@web.de)

## Featured Products



Qty.	REF	Description
1	70 04 62	<b>RaVoR™</b> bipolar electrode "Binner" for inferior turbinates with protective insulation, working length 110 mm



### 87 00 10 – CURIS® basic set with single-use patient plates

Qty.	REF	Description
1	36 01 00-01	<b>CURIS®</b> 4 MHz radiofrequency generator (incl. main cord, user manual and test protocol)
1	36 01 10	Footswitch two pedals for CURIS® (cut & coag), 4 m cable
1	37 01 54L	Bipolar cable for CURIS®, length 3 m
1	36 07 04	Monopolar handpiece (pencil) cut & coag, shaft 2.4 mm, cable 3 m
1	36 02 38	Cable for single-use patient plates, length 3 m
1 (x50)	36 02 22	Safety patient plates, single-use, packing 5 x 10 pcs. (not shown)

#### Unit settings\*

**CURIS®** 4 MHz radiofrequency generator  
**RaVoR™** bip. electrode: Bipolar RaVoR™, AUTOSTOP  
 Power adjustment: 10 watts

**CURIS®** 4 MHz radiofrequency generator  
**RaVoR™** bip. electrode: Bipolar RaVoR™, AUTOSTOP  
 Power adjustment: 10 watts

Valid for the **CURIS®**  
 with the orange label.



\* Please consider that this information is not meant to serve as a detailed treatment guide. Always adjust according to patient and application.



**SUTTER MEDIZINTECHNIK GMBH**

ALFRED-WALZ-STR. 22 · 79312 EMMENDINGEN/GERMANY · TEL. +49(0)7641-96256-0

FAX +49(0)7641-96256-30 WWW.SUTTER-MED.COM · INFO@SUTTER-MED.DE