

Radiofrequency Volumetric Reduction (RaVoR™) for Non-Allergic and Non-Infectious Perennial Rhinitis

By Raffaello Romeo and Maurizio Luce, ENT Consultants, Rome, Italy and Giampietro Zambetti, MD, Assistant Professor, University of Rome "La Sapienza" Rome, Italy

The most common anatomical cause of nasal obstruction is hypertrophy of the inferior turbinates. It is mostly associated with a deviated septum, a general chronic rhinitis or aspecific nasal hyperactivity (ANH) [1]. The ENT specialist is often faced with the decision to either adopt a long-term medical treatment or to choose a surgical procedure. This is due to the high incidence, especially in patients with a non-allergic and non-infectious perennial rhinitis (NANIPER), where ANH is a major feature. This paper describes our experience with the RaVoR™ of inferior turbinates in NANIPER patients and its effects on ANH.

Introduction: Over the years many surgical techniques have been developed, and many technologies have been applied for the treatment of hypertrophic turbinates. The method of choice should not only feature good clinical results, but also be safe, fast and easy to learn, and easy to perform as an outpatient treatment. The possible reduction of the discomfort for the patients as well as reasonable costs of the therapy have to be considered when choosing a treatment method. RaVoR™ with CURIS® (Figure 3) and BM-780 II (Sutter, Germany) cover all the above-mentioned criteria and are our treatment of choice.

Materials and Methods: We treated 50 NANIPER patients: 35 female and 15 male, ranging from 17 to 81 years of age with an average of 42 years. They all showed symptoms of chronic nasal obstruction. Significant septum deviation had been excluded and none of the patients responded to local or general medical treatment. Endoscopic inspection of the nasal cavity was performed before the intervention, 12 and 24 months postoperatively. The cross-sectional areas (CSA) and the corresponding nasal resistance (NR) were evaluated by acoustic rhinometry 15 minutes before and 15 minutes after an aspecific nasal provocation test (ANPT). During each visit Tremble's mucociliary transport test (MCT) was also performed.

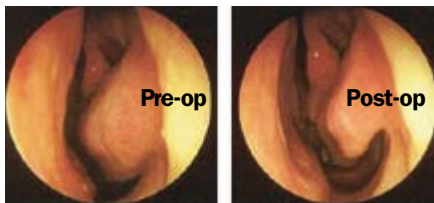


Figure 1: Inferior turbinate – preoperative condition and six months postoperatively with significantly enlarged nasal passage.

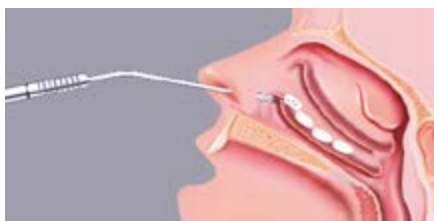

Figure 2: Schematic view of the puncture sites for the RaVoR™ treatment of hypertrophic turbinates.

The RaVoR™ procedure was always performed under local anesthesia, but without infiltration. One strip of cotton soaked with lidocaine spray was placed in each nasal passage for ten minutes. The patients were in supine position with the head and shoulders raised up and supported. The reusable bipolar turbinate probe "Binner" (REF 70 04 62) and the generators BM-780 II (level 2, i.e. 6 watts, total energy ≤ 54 joules) or CURIS® (10 watts, RaVoR™ mode, AutoStop, total energy ≤ 100 Joule) were used to create 4 to 5 lesions (Figure 2). To reach the posterior part of the nasal cavity a lateralization of the turbinate was performed. Afterwards the patients were sent home and advised to use saline solution for 2 to 3 weeks. Nasal tamponades were never required.

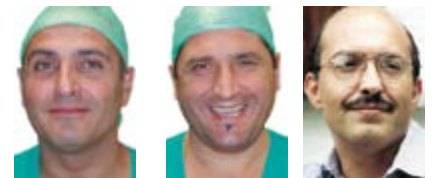
Results: Compared to the preoperative condition, all the CSA values after RaVoR™ treatment increased. They were recorded both 12 and 24 months postoperatively, measured before and after the ANPT. After 24 months the CSA values began to decrease slightly again. It is noteworthy that before treatment an ANPT reduced the CSA by approximately 40 % to 50 % while by only 15 % 12 and 24 months postoperatively. Moreover, after RaVoR™, the patients showed only little ANH symptoms. Similar results can be observed for the postoperative NR scores, which showed an improvement compared to preoperative condition, before and after the ANPT. The NR scores increased 24 months postoperatively, but remained below the preoperative values. Finally, the MCT test showed an improvement of the ciliary beat. Transport times were shorter compared to the preoperative condition 12 and 24 months postoperatively.

Discussion: Our results indicate that the surgical RaVoR™ treatment of NANIPER patients can enlarge the airways and improve respiratory obstruction. Postoperatively the results last for as long as two years. This is confirmed by improved CSA and reduced NR values during a two year study period. The ciliary beat was improved for a period of two years, as clearly shown by MCT scores. The findings indicate that there is no damage to the mucosa resulting from the treatment. The clinical results do not differ in female and male patients. Furthermore, we did not observe any side ef-



Figure 3: CURIS® radiofrequency unit (Sutter Medizintechnik GmbH, Germany)

fects during the application of radiofrequency energy or after the treatment. The radiofrequency treatment RaVoR™ is a modern surgical technique showing good and long-lasting treatment results when used to reduce the volume of hypertrophic turbinates. At the same time it preserves the mucosa and its function. It is a safe, easy and fast outpatient procedure. Moreover, thanks to the reusable accessories and compared with other treatment methods, health care systems benefit from the significantly reduced costs of the therapy. In our opinion the radiofrequency volume reduction RaVoR™ is the best treatment option for NANIPER patients with significant nasal obstruction, especially when combined with the long-term medical treatment to control ANH. It may be indicated to repeat RaVoR™ application.



Romeo R., MD Luce M., MD Zambetti G., MD

Correspondence: Raffaello Romeo, MD ENT Consultant, Via G.L. Squarcialupo, 2, 00162 Rome, Italy, E-Mail: raffaello.romeo@libero.it

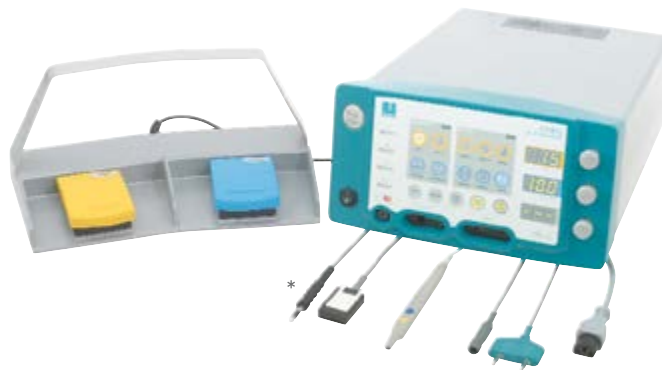References: 1. Gerth Van Wijk R. et al. (1999) Nasal hyperactivity. *Rhinology* 37:50-5 2. Fililaci F. et al. (1996) The behaviour of non-specific nasal provocation tests in subjects with allergic rhinitis and not, in and out of crisis: a longitudinal study. *Allergol. et Immunopathol.* 24:158-62 3. Kizilkaya Z. et al. (2008) Comparison of radiofrequency tissue volume reduction and submucosal resection with microdebrider in inferior turbinate hypertrophy. *Otolaryngol. Head Neck Surg.* 138(2):176-81

Featured Product



700462 – Bipolar needle electrode "Binner"

Qty.	REF	Description
1	700462	Bipolar needle electrode "Binner" with protective insulation, work length 110 mm



870010 – CURIS® basic set with single-use patient plates

Qty.	REF	Description
1	360100-01	CURIS® radiofrequency generator (incl. mains cord, user manual and test protocol)
1	360110	Footswitch with two pedals for CURIS® (cut & coag), 4 m cable
1	370154 L	Bipolar cable for CURIS®, length 3 m
1	360704	Monopolar handpiece (pencil) cut & coag, shaft 2.4 mm, cable 3 m
1	360236	Cable for single-use patient plates, length 4.5 m
1 (x50)	360222	Safety patient plates, single use, packing 5 x 10 pcs. (not shown)
Optional		
1*	360226	Patient plate with cable, re-usable, length 4 m

Unit settings / Other accessories*

CURIS®
Bipolar electrode: Bipolar RaVoR™
Power adjustment: 10 watts

CURIS®
Bipolar electrode: Bipolar RaVoR™
Power adjustment: 10 watts

* Please consider that this information is not meant to serve as a detailed treatment guide. Always adjust according to patient and application.



SUTTER MEDIZINTECHNIK GMBH

ALFRED-WALZ-STR. 22 · 79312 EMMENDINGEN/GERMANY · TEL. +49 (0)7641 96256-0 · FAX +49 (0)7641 96256-30
WWW.SUTTER-MED.COM · WWW.SUTTER-MED.DE · E-MAIL : INFO@SUTTER-MED.DE