

Radiofrequency assisted volumetric reduction of the tongue base in cases of obstructive sleep apnea

B. Vyshanavi, D. S. Deenadayal

Sleep-related breathing disorders have gained popularity in the recent times especially in the medical fraternity because of its potential consequences. Obstructive sleep apnea is a condition characterized by obstruction of the upper airway resulting in apneas or hypopneas. Among the various anatomical sites of obstruction, tongue base is supposed to play a major role in causing collapse of the upper airway in patients with severe obstructive sleep apnea.




Fig. 1: RaVoR™ bipolar electrode for the tongue base (REF 70 04 99)

Introduction: Various anatomical sites of obstruction have been known to play a significant role in cases of obstructive sleep apnea. A relative or true enlargement of the tongue base can compromise the oropharyngeal space.^[1] True enlargement of the tongue base occurs as a result of either lymphoid tissue hypertrophy or muscular tissue hypertrophy. A relative hypertrophy of the tongue base occurs as a result of mandibular abnormalities like retro-position of mandible.

Addressing the tongue base surgically is difficult due to its anatomical location, proximity to vital structures like lingual artery resulting in risk of excessive bleeding during surgery, difficulty in visualizing the operative site, and lack of appropriate instrumentation to reduce the tongue base.

In this report we present our case series where the tongue base tissue has been reduced with (Radiofrequency Volume Reduction) RaVoR™ bipolar electrode for the tongue base (Fig. 1) in a single sitting.

Patients and Methods: We evaluated a total of 150 patients diagnosed with obstructive sleep apnea in a period of one year, out of which 5 patients missed the follow-up and 4 patients did not return back, so we were

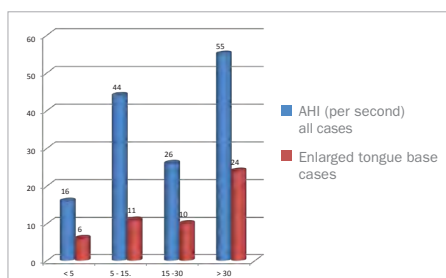


Fig. 2: AHI in patients with obstructive sleep apnea.

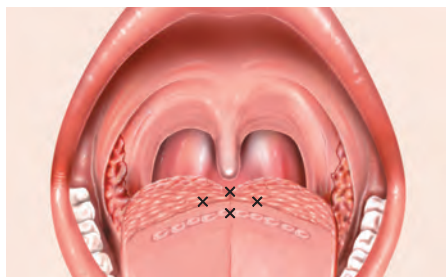


Fig. 3: Puncture sites on the tongue base for the application of radiofrequency.

left with a total of 141 patients and out of them 51 patients had an enlarged tongue base. An overnight polysomnography and fiberoptic laryngopharyngoscopy with Muller's maneuver was done in these patients and it was observed that among the cases with severe obstructive sleep apnea [AHI>30] 43% of the patients had tongue base enlargement with or without other anatomical sites of obstruction (Fig. 2).

These patients were taken up for radiofrequency assisted volumetric reduction of the tongue base. The procedure was performed as part of a nasal +/- palatal procedure. Under general anesthesia with all sterile precautions the tongue was pulled forward. The tongue base was visualized with a 700 Hopkins rod-lens telescope. The sites for application for radiofrequency current were marked as shown in the diagram below (Fig. 3). A current of 12 watts was applied at the sites with (Radiofrequency Volume Reduction) RaVoR™ bipolar electrode for the tongue base (Sutter, REF 70 04 99).

Following the procedure the patients were observed in the hospital for 24 hours and then discharged. No major complications have been reported intraoperatively and postoperatively except for mild discomfort in the throat and

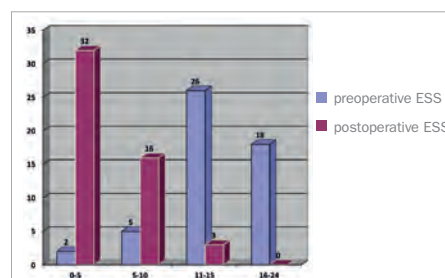


Fig. 4: Graph showing postoperative ESS score.

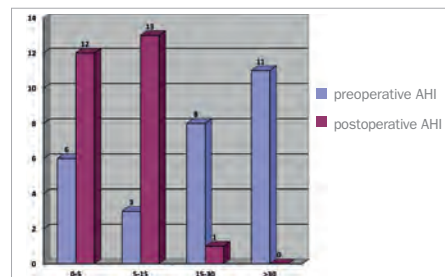


Fig. 5: Graph showing postoperative improvement of AHI.



Fig. 6: CURIS® 4 MHz radiofrequency generator

painful swallowing. Our patients were followed up for a period of one year.

Results: 51 patients underwent radiofrequency assisted volumetric reduction of the tongue base. The improvement was assessed by subjective reduction in snoring, reduced body mass index, and reduction in the ESS scores. All patients reported subjective improvement in snoring and improvement in the ESS score (Fig. 4).

We advised a repeat sleep study to all our patients but due to financial concerns a repeat sleep study and comparative assessment of AHI could not be done on all patients. 26 patients underwent a repeat sleep study. The improvement in AHI is shown in the chart below (Fig. 5).

Conclusion: Radiofrequency assisted reduction of the tongue base is a minor yet effective procedure to address patients with true tongue base enlargement. As it is minimally invasive and potential risks of complications are low it can be performed by young surgeons as well. Repeated application may be required to achieve good results in a few patients. In our study single application of radiofrequency current to the tongue base was found to be effective.



Dr. B. Vyshanavi, Dr. D. S. Deenadayal
Aarti Clinic, 9-1-193, St. Mary's Road
Secunderabad-500 003, India

References: 1. Surgical management of obstructive sleep apnea Pushkar Mehra, BDS, DMD1 and Larry M. Wolford, DMD corresponding author.

Featured Products



134° C autoclavable  



RaVoR™ (Radiofrequency Volume Reduction)

Qty.	REF	Description
1	70 04 99	RaVoR™ bipolar electrode for the tongue base with protective insulation, work length 110 mm



[REF 87 00 10] CURIS® 4 MHz radiofrequency generator
basic set with single-use patient plates

Qty.	REF	Description
1	36 01 00-01	CURIS® 4 MHz radiofrequency generator (incl. main cord, user manual and test protocol)
1	36 01 10	Footswitch two pedals for CURIS® (cut & coag), 4 m cable
1	37 01 54L	Bipolar cable for CURIS®, length 3 m
1	36 07 04	Monopolar handpiece (pencil) cut & coag, shaft 2.4 mm, cable 3 m
1	36 02 38	Cable for single-use patient plates, length 3 m
1 (x50)	36 02 22	Safety patient plates, single-use, packing 5 x 10 pcs. (not shown)



Unit settings / Other accessories*

CURIS®
4 MHz radiofrequency generator

RaVoR™ bipolar electrode: RaVoR™
Power adjustment: 12 watts

Valid for the **CURIS®**
with the orange label.



CURIS®
4 MHz radiofrequency generator

RaVoR™ bipolar electrode: RaVoR™
Power adjustment: 12 watts

* Please consider that this information is not meant to serve as a detailed treatment guide. Always adjust according to patient and application.



SUTTER MEDIZINTECHNIK GMBH

TULLASTRASSE 87 · 79108 FREIBURG/GERMANY · TEL. +49(0)761-51551-0 · FAX +49(0)761-51551-30

WWW.SUTTER-MED.COM · INFO@SUTTER-MED.DE