

Treatment of telangiectasia of the face using radiofrequency

Christian Jacobi, Clemens Heiser

Telangiectasia frequently occurs in the head and neck dermis, especially in the nasal and auricular area. Various treatment options are available, such as chemical (sclerotherapy), thermal (radiofrequency (=RF), laser therapy and pulsed light) and microsurgical therapies. This application report presents the possibility of treating telangiectasias with RF as a highly effective treatment modality for head and neck surgeons and ENT professionals to extend the use of their radiofrequency devices in a clinical routine.



Fig. 1: ARROWtip™ monopolar microdissection electrode (36 03 21)

Introduction: Telangiectasias are defined as dilated blood vessels (venules, capillaries or arterioles) with a diameter up to 1mm, located in the skin and mucous membranes. Various predisposing factors are described, such as rosacea, topical steroid use, photodamage, genetic factors and systemic disorders.^{1,2} The optimal treatment regime is mainly dependent on the size and depth of the targeted vessels: the gold standard for spider/reticular veins with a size >1mm is sclerotherapy, blood vessels smaller than 1mm however, may be too small to treat via sclerotherapy.^{3,4} Furthermore, co-factors such as needle phobia and allergy, require treatment alternatives. In these cases, RF can be applied in an either supplementary or alternative manner. Radiofrequency technology enables tissues to be dissolved at a relatively low temperature through energized electrolytes (particularly sodium ions).⁵ This energy can be delivered focally allowing minimal damage to the surrounding tissue. In cases of telangiectasias, RF induces the electrodissection of the squamous epithelium and the papillary reticular dermis on the level of the vessel.⁴ The resulting slight warming in the targeted vessel causes blood coagulation and

fusion of vessel walls with one another, and can be observed as an immediate blanching.⁴

Case study: The patient in this case has been suffering from untreated progressive telangiectasias of the facial skin for many years. Due to a livid coloring of the nasal tip, he asked for unifocal treatment. The largest telangiectasias were seen in the nasal supratip area and the cephalic rim of the lateral nasal wall measuring around 0.6 – 1.0mm. In addition, smaller vessels <0.5mm were all around the nasal dorsum (see Fig. 2).

Methods: The CURIS® 4 MHz radiofrequency generator (Sutter, Germany) was adjusted to a maximum of 3 watts in “Softspray” mode (s. Fig. 4). A non-alcoholic disinfectant was applied, topical anaesthetics were not necessary. A tiny, hair-thin electrode was inserted in the hand-held monopolar device (ARROWtip™ monopolar microdissection electrode, short-angled, s. Fig. 1). The needle was placed in an orthogonal angle to the vein with gentle pressure (Fig. 3). The radiofrequency energy can be released either with the finger button on the monopolar device, or preferably with the foot switch to avoid further tremor of the hand. It is further recommended to start with peripheral vessels, continuing in a centripetal pattern. Once blanching of the vessel is observed, sufficient energy has been applied. Small vessels (approx. <0.5mm), experience a more immediate and thorough vessel fusion. If blanching is not immediately observed the energy can be repeatedly applied; but it is crucial not to alter the epidermis too extensively. After a follow-up period of around 4 weeks (including skin-moisturizing for approximately 2 weeks), residual vessels can be treated again if there are no skin alterations (dyspigmentation, scarring).

Discussion: The high precision of the RF thin monopolar needle allows detailed treatment of small vessels by minimizing longitudinal injury of the epithelial and reticular dermis in patients with facial telangiectasias. The risk of scarring is very low if the treatment is performed cautiously with the appropriate setting. Temporary hyperemia and gentle crusting in the diameter of the applied needle may occur if the epithelium has been injured. Re-epithelialization is secured by stem cells, that are typically not affected by RF.⁶ However, one should inform the patient about



Fig. 4: CURIS® 4 MHz radiofrequency generator

the risk of dyspigmentation and (especially) hyperpigmentation, as well as local recurrence. The method of RF is limited in the treatment of larger vessels, which do not show immediate blanching. In these cases, the risk of dermal injury with subsequent skin alterations and scarring rises, as too much energy may be applied. Local cooling of the skin reduces the heating and the subsequent injury of the epidermis – a method frequently used in cosmetic indications, such as facial rejuvenation.⁷

Conclusion: RF is a highly effective and safe treatment option for small facial telangiectasias of less than 1mm in diameter.



C. Jacobi, MD; C. Heiser, MD
University Hospital rechts der Isar TUM,
Munich, Germany

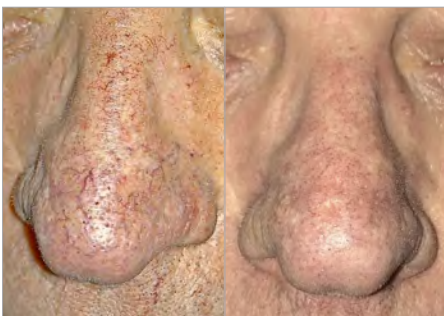


Fig. 2: Pre- and post-RF images of nasal telangiectasia: Note the telangiectasias with its livid coloring of the nose (left image).

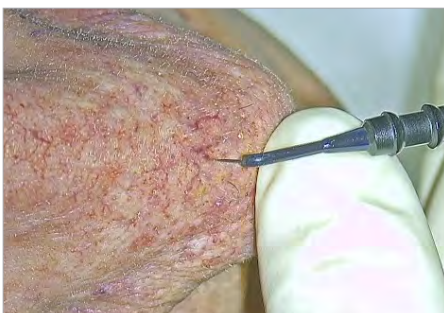

Fig. 3: RF treatment of telangiectasia of the nose

Please turn over the page for detailed information on the Sutter products.

As seen in: ent and audiology news | July/August 2019 | VOL 28 NO 3 | Page 32

Correspondence: Department of Otorhinolaryngology, Head and Neck Surgery, Technical University, Munich, Germany, christian.jacobi@tum.de

References: 1. Karppinen T, Kantola E, Karppinen A, et al. Treatment of telangiectasia on the cheeks with a compact yellow (585 nm) semiconductor laser and a green (532 nm) KTP laser: a randomized double-blinded split-face trial. *Lasers Surg Med.* 2019. 2. Schieving JH, Schoenaker MHD, Weemaes CM, et al. Telangiectasias: Small lesions referring to serious disorders. *Eur J Paediatr Neurol.* 2017;21(6):807-815. 3. Meesters AA, Pitassi LH, Campos V, Wolkerstorfer A, Dierckx CC. Transcutaneous laser treatment of leg veins. *Lasers Med Sci.* 2014;29(2):481-492. 4. Bush R, Bush P. Histological findings correlated with clinical outcomes in telangiectasia treated with ohmic thermolysis and 940 nm laser. *J Cosmet Dermatol.* 2018;17(5):779-782. 5. Maness W L, et al. Histologic evaluation of electrosurgery with varying frequency and waveform. *J Prosthet Dent.* V40, N 3. 1978. 304-308. 6. Lau K, Paus R, Tiede S, Day P, Bayat A. Exploring the role of stem cells in cutaneous wound healing. *Exp Dermatol.* 2009;18(11):921-933. 7. Paasch U, Bodendorf MO, Grunewald S, Simon JC. Skin rejuvenation by radiofrequency therapy: methods, effects and risks. *J Dtsch Dermatol Ges.* 2009;7(3):196-203.

For more information:
+49 (0)7641 962560
info@sutter-med.de
www.sutter-med.de



Featured Products



Qty.	REF	Description
2	36 03 20	ARROWtip™ monopolar microdissection electrode Ø 0.3 mm, 45° angled, total length: 56 mm



Qty.	REF	Description
2	36 08 04	Needle electrode Ø 0.3 mm, straight, total length: 67 mm



[REF 87 00 10] CURIS® 4 MHz radiofrequency generator
basic set with single-use patient plates

Qty.	REF	Description
1	36 01 00-01	CURIS® 4 MHz radiofrequency generator (incl. mains cord, user manual and test protocol)
1	36 01 10	Footswitch two pedals for CURIS® (cut & coag), cable: 4 m
1	37 01 54L	Bipolar cable for CURIS®, length: 3 m
1	36 07 04	Monopolar handpiece (pencil) cut & coag, shaft 2.4 mm, cable: 3 m
1	36 02 38	Cable for single-use patient plates, length: 3 m
1 (x50)	12 80H	Patient plates, single-use, 5 x 10 pcs. (not shown)

Unit settings / Other accessories*

CURIS®
4 MHz radiofrequency generator

Monopolar ball electrode: Monopolar CUT 1
Power adjustment: 4 to 10 watts

Valid for the **CURIS®**
with the orange label.



CURIS®
4 MHz radiofrequency generator

Monopolar ball electrode: Monopolar CUT 1
Power adjustment: 18 to 30 watts

* Please consider that this information is not meant to serve as a detailed treatment guide. Always adjust according to patient and application.

Product availability is subject to regulatory approval in individual markets. Products may therefore not be available in all markets. Lengths for orientation purposes; may vary slightly.



PRECISION ELECTROSURGERY
Made in Germany

SUTTER MEDIZINTECHNIK GMBH
ALFRED-WALZ-STR. 22 · 79312 EMMENDINGEN/GERMANY
TEL. +49(0)7641-96256-0 · FAX +49(0)7641-96256-30
WWW.SUTTER-MED.COM · INFO@SUTTER-MED.DE