

# Feasibility of Radiofrequency Resection in Oral and Oropharyngeal Tumor Surgery – A Case Series

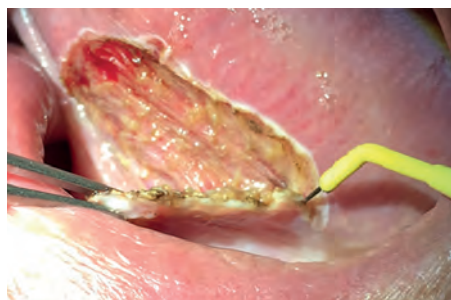B. Hofauer, C. Heiser



**Fig. 1:** ARROWtip™ monop. microdissection electrode (REF 36 03 42)

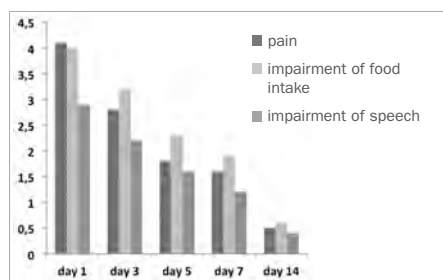
**Introduction:** Several methods are available for transoral resection of benign or malignant tumors in the oral cavity and the oropharynx. Besides classic cold steel resection, monopolar electrosurgery and CO<sub>2</sub>-laser resections have been established as resection methods for such tumors. In earlier research projects, radiofrequency-assisted surgery proved to be successful for the resection of pathological findings and achieved a good combination of radicality and hemostasis compared to other techniques. The aim of this study was to show the feasibility of radiofrequency-assisted resections of oral and oropharyngeal tumors on the basis of several parameters.

**Material and Methods:** All patients with oral or oropharyngeal tumors were included. Excluded were patients who had undergone preliminary radiation of the head and neck; who had a tumor of a size that would have required further reconstruction or an extended surgical approach. An excision was performed with the CURIS® 4 MHz radiofrequency generator (REF 36 01 00-01, Sutter Medizintechnik, Freiburg, Germany) using an ARROWtip™ monopolar microdissection electrode (REF 36 03 42, Fig. 1 and 2). Radiofrequency was evaluated with perioperative parameters (bleeding, tissue sticking, coagulation, user friendliness), objective postoperative parameters (wound healing, postoperative complications) and subjective postoperative parameters (visual analogue scale for the assessment of pain, impairment of food intake, impairment of speech). The surgical specimen was evaluated with regard to the completeness of the resection, width of the coagulation margin and the quality of the resection margin.



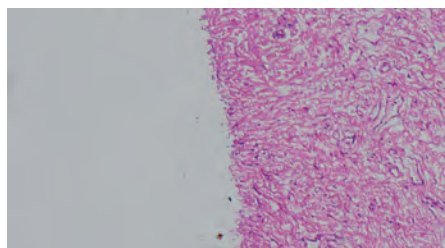
**Fig. 2:** Radiofrequency-assisted resection of an oral leukoplakia of the bottom of the tongue.

**Results:** Between December 2014 and December 2015, twenty patients were included in the study (10 male, 10 female, average age 57.5 years), 12 patients of whom were suffering from benign and 8 from malignant lesions. 11 patients were operated under general anesthesia and 9 patients under local anesthesia. Intraoperative bleeding was rated as followed: no bleeding 5/20, predominantly self-limiting 5/20 and predominantly with pressure 10/20 (predominantly with coagulation 0/20 and ligation 0/20). In 10/20 cases there was no intraoperative tissue sticking, in 10/20 cases tissue sticking could be resolved through activation of radiofrequency. Coagulation was limited to the area of resection and surgeons rated the user-friendliness of radiofrequency as comfortable. Objective postoperative parameters were evaluated on day 1, 3, 5, 7 and 14. No impairment of wound healing or postoperative complications could be observed. Results of the survey on subjective postoperative parameters are shown in figure 3.



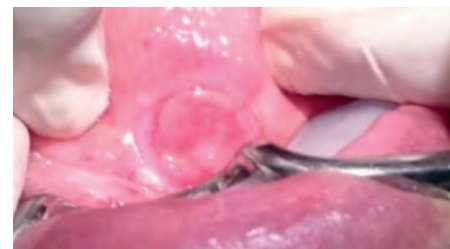
**Fig. 3:** Course of subjective postoperative parameters evaluated with visual analogue scales (ranging from 0-10).

Radiofrequency did not have any impact on the assessment of the surgical specimen by the pathologist. Resection margins were graded as predominantly smooth. The width of the coagulation margins was below 500 µm in every patient (Fig. 4).




**Fig. 4:** Smooth resection margin without significant coagulation artifacts (with the friendly permission of Dr. Gregor Babaryka, Institute for Pathology, Technical University Munich).

**Discussion:** Resection of tumors in the oral cavity and the oropharynx require careful consideration of the functional properties. The oropharynx is part of the upper airway; the oropharynx and the oral cavity are both involved in the ingestion of food and in the articulation of speech. The present case series has demonstrated a rapid post-op improvement of these significant functions after resection of tumorous lesions while adverse events were not observed (Fig. 5). Despite efficient intraoperative hemostasis the surgical specimen did not show any significant alteration from excessive coagulation, which might have affected the pathological evaluation. We observed no lingual muscle stimulation with the CURIS® 4 MHz radiofrequency generator which is an advantage especially for patients under local anesthesia.



**Fig. 5:** Site of resection 14 days after surgery.

**Conclusion:** 4 MHz Radiofrequency is a suitable tool for the resection of tumors in the oral cavity and the oropharynx.



**Dr. B. Hofauer, Dr. C. Heiser**  
Klinikum rechts der Isar (Munich, Germany)

**Correspondence:** Otorhinolaryngology / Head and Neck Surgery, Klinikum rechts der Isar, Technical University Munich, Ismaninger Str. 22, 81675 Munich, b.hofauer@tum.de

**References:** 1. Heiser C, Knopf A. Resection of Squamous Cell Carcinoma of the Tongue Using Radiofrequency Surgery: A Case Report. *ENT & audiology news* 2014 Jan/Feb;22(6): 16. 2. Basterra J, Fraix S, Alba JR, Zapster E. A new device for treating laryngeal carcinoma using microdissection electrodes. *Laryngoscope* 2006 Dec;116(12): 2232-4. 3. Basterra J, Zapster E, Moreno R, Hernández R. Electrosurgical endoscopic cordectomy with microdissection electrodes. A comparative study with CO<sub>2</sub> laser chordectomy. *J Laryngol Otol* 2006 Aug;120(8): 661-4. 4. Hoffmann TK, Schuler OJ, Bankfalvi A, Greve J, Heusgen L, Lang S, Mattheis S. Comparative analysis of resection tools suited for transoral robot-assisted surgery. *Eur Arch Otorhinolaryngol* 2014 May;271(5):1207-13

# Featured Products



Qty.	REF	Description
2	36 03 42	<b>ARROWtip™</b> monopolar microdissection electrode, straight, Ø 2.4 mm, total length 107 mm, 45° angled



[REF 87 00 10] **CURIS®** 4 MHz radiofrequency generator  
basic set with single-use patient plates



Qty.	REF	Description
1	36 01 00-01	<b>CURIS®</b> 4 MHz radiofrequency generator (incl. main cord, user manual and test protocol)
1	36 01 10	Footswitch two pedals for CURIS® (cut & coag), 4 m cable
1	37 01 54L	Bipolar cable for CURIS®, length 3 m
1	36 07 04	Monopolar handpiece (pencil) cut & coag, shaft 2.4 mm, cable 3 m
1	36 02 38	Cable for single-use patient plates, length 3 m
1 (x50)	36 02 22	Safety patient plates, single-use, packing 5 x 10 pcs. (not shown)

### Unit settings / Other accessories\*

**CURIS®**  
4 MHz radiofrequency generator

**ARROWtip™** microdissection electrode: Monopolar CUT 2  
Power adjustment: 12 watts

Valid for the **CURIS®**  
with the orange label.



**CURIS®**  
4 MHz radiofrequency generator

**ARROWtip™** microdissection electrode: Monopolar CUT 2  
Power adjustment: 25 to 40 watts

\* Please consider that this information is not meant to serve as a detailed treatment guide. Always adjust according to patient and application.



SUTTER MEDIZINTECHNIK GMBH

TULLASTRASSE 87 · 79108 FREIBURG/GERMANY · TEL. +49(0)761-51551-0 · FAX +49(0)761-51551-30

WWW.SUTTER-MED.COM · INFO@SUTTER-MED.DE