

Treatment of Patients with Chronic Dacryocystitis with the CURIS® 4 MHz Radiofrequency Generator: Clinical Case Report.

Prof. V.M. Svistushkin, P. Pryanikov, E. Isaev, ENT Clinic, Moscow Regional Scientific Research Clinical Institute n.a. M.F. Vladimírsky, Russia

Dacryocystitis (inflammation of the lacrimal sac) ranks high among eye disorders. It is complex and often has severe consequences. Dacryocystorhinostomy (DCR) is the most popular method to treat drainage problems of the lacrimal duct, but bears the risk of leading to chronic, traumatic and congenital forms of dacryocystitis. Novel methods such as the endoscopic endonasal approach and radiofrequency offer an attractive alternative to conventional treatment methods.

Introduction: Complications from incisions after traditional surgery in dacryocystitis range from 1% to 25% and average at 13%. They are on-efficient techniques, scar formation, and the continuation of the pathological development in the nasal cavity and sinuses [1,2,3,5,7,8]. Endoscopic DCR is time-saving and less traumatic. It prevents scarring while tissue is spared, and contributes to the formation of the desired stoma. This generally reduces the risk of relapses and provides a stable outcome. Studies have shown that the effectiveness of DCR is usually higher than 90%. [10, 11]. The latest findings in ENT show that radiofrequency has become a method of choice for endonasal DCR with a long-term success rate of more than 98% [12]. We have chosen a novel approach using the CURIS® 4 MHz radiofrequency RF Generator (Sutter Medizintechnik GmbH, Freiburg/Germany) (Fig. 1) for performing DCR.



Fig. 1: CURIS® 4 MHz RF unit (Sutter, Germany)

Materials and methods: In 2012 and 2013 ten patients diagnosed with dacryocystitis underwent surgery in our clinic (7 male, 3 female, age 28 to 59). All patients had suffered from chronic dacryocystitis for more than one year and conventional treatment had proven ineffective. Prior to the intervention, standard clinical examinations and laboratory testing were performed and X-rays were taken. In one case, the CT scan of a 29-year old patient showed a „giant“ lacrimal sac. After consultation with the ophthalmologist, surgery was advised. Patient preparation was standard. The patient was positioned on his back with the head section of the operating table elevated.

Under general anesthesia a portion of the lateral nasal wall was resected by means of a U-shaped cut. The lower lacrimal point was identified by insertion of a cannula probe and stent in the nasal cavity under endoscopic visualization. After removal of the lacrimal bone the medial part of the lacrimal sac was

exposed. Under endoscopic visualization the lower lacrimal point was identified with a Bowman electrode inserted through the nasal cavity. The lacrimal sac partition was dissected with an ARROWtip™ monopolar microdissection electrode (REF 36 03 65 WL 65 mm, Sutter Medizintechnik GmbH, Freiburg/Germany) and the CURIS® 4 MHz RF generator in monopolar mode (Fig. 2; settings: CUT 1 in cutting mode; CONTACT mode for coagulation; power range 18 to 24 watts).

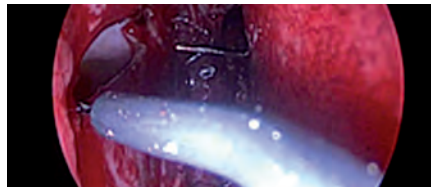


Fig. 2: Lacrimotomy with RF generator CURIS®

The CURIS® 4 MHz RF generator achieved a high level of precision and proved to be time-saving during the intervention. No bleeding or damage of the surrounding tissue occurred. DCR with the CURIS® 4 MHz RF generator takes only about 3 to 5 minutes compared to conventional methods requiring, in our institution, 10 to 15 minutes. The existing U-shaped tissue flap was partially removed and attached to the edge of the partition of the lacrimal sac. Coagulation was gentle and smooth, and total blood loss was less than 50 ml. Finally a Ritleng silicone stent (FCI, France) was inserted (Fig. 3).

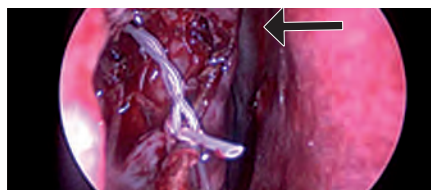


Fig. 3: Endoscopic visualization of silicone stents in the lacrimal duct

The stoma was filled with hemostatic sponge. Overall the operation does not exceed 40-50 minutes and patients tolerate it well. Postoperative evaluation was based on visual analog scales and daily endoscopic examination. On the 3rd and 5th day after surgery a slight swelling and redness around the surgical field was observed. On the 10th day the edema was significantly reduced and the mucosa turned pink again. Two months postoperatively the silicone stents were removed. Follow-up after 6 months showed a functional opening of the lacrimal duct. Only a soft pale pink scar remained around the edges (Fig. 4).

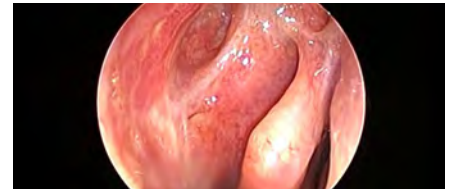


Fig. 4: Endoscopic view six months after DCR. Reopened lacrimal duct

The postoperative period was generally uneventful. Wound secretion was insignificant. Only minor pain was noted. Tissue healing was rapid, and no complications were observed.

Results: Endoscopic DCR with the CURIS® 4 MHz RF generator has the following benefits: very precise surgical outcomes; exact coagulation; convenient cutting mode; minimal damage to the surrounding tissue; simplicity and versatility of the applied ARROWtip™ electrode; easy dissection; minimal bleeding from incision.

Conclusion: The first use of the CURIS® 4 MHz RF generator for endoscopic DCR surgery by lacrymo-nasal approach turned out to be highly successful and may be the method of choice for carrying out such interventions.



Prof. V.M. Svistushkin P. Pryanikov, E. Isaev

Correspondance:

Svistushkin V.M. (PhD. MD) Head of ENT Clinic MO-NKI named after M.F. Vladimírskiy Moscow RUSSIA
Email svvm3@yandex.ru; Tel +74956313345

References:

1. Азнабаев М.Т. et al, Современные аспекты офтальмологии.- Казань, 2004.- С. 10-14.
2. Белогазов В.Г., VI съезд отоларингологов СССР.- М., 1975.- С. 48-49.
3. Белогазов В.Г. et al, Вестн. офтальмол.- 1999.- №5.- С. 14-16.
4. Волков В.В. et al, дакриоцисториностомия.- Л.,1975.- 104 с.
5. Саад Ельдин Н.М. Анализ причин и меры предупреждения развития рецидивов после дакриоцисториностомии: Дис. Еканд. мед. наук.- М., 1998.
6. Черкунов Б.Ф. Болезни слезных органов.- Самара, 2001.- С. 215-273.
7. Busse H., Muller K. N., Klin. Mbl. Angenheilk.- 1997.- Bd. 170.- № 4.- S. 627-632.
8. Mauriello J.A. et al, Ophthal. Plast. Reconstr. Surg.- 1992.- Vol.- 8.- № 1.- P. 13-21.
9. Tarbet K.J., Custer P.L., Ophthalmology.- 1995.- Vol. 102.- № 7.- P. 1065-1070.
10. Javate RM, Pamintuan FG. Endoscopic radiofrequency assisted DCR (ERA-DCR) with double stent: a personal experience. Orbit 2005; 24(1):15-22.
11. Tsribas A., Wormald P.J. Endonasal dacryocystorhinostomy with mucosal flaps. Am J Ophthalmol 2003; 135(1):76-78.
12. Ramakrishnan V.R. et al, Kingdom TT. Outcomes after endoscopic dacryocystorhinostomy. J Laryngol Otol 2004; 118 (4):267-269.

Featured Products



Qty.	REF	Description
2	36 03 65	ARROWtip™ monopolar microdissection electrode, Tonsillotomy, total length 112 mm



87 00 10 – CURIS® basic set with single use patient plates

Qty.	REF	Description
1	36 01 00-01	CURIS® 4 MHz radiofrequency generator (incl. main cord, user manual and test protocol)
1	36 01 10	Footswitch two pedals for CURIS® (cut & coag), 4 m cable
1	37 01 54L	Bipolar cable for CURIS®, length 3 m
1	36 07 04	Monopolar handpiece (pencil) cut & coag, shaft 2.4 mm, cable 3 m
1	36 02 38	Cable for single-use patient plates, length 3 m
1 (x50)	36 02 22	Safety patient plates, single-use, packing 5 x 10 pcs. (not shown)

Unit settings / Other accessories*

CURIS® 4 MHz radiofrequency generator
ARROWtip™ electrode: Monopolar CUT 1 or CONTACT
 Power adjustment: 18-24 watts

CURIS® 4 MHz radiofrequency generator
ARROWtip™ electrode: Monopolar CUT 1 or CONTACT
 Power adjustment: 25-40 watts

Valid for the **CURIS®**
 with the orange label.



* Please consider that this information is not meant to serve as a detailed treatment guide. Always adjust according to patient and application.



SUTTER MEDIZINTECHNIK GMBH

ALFRED-WALZ-STR. 22 · 79312 EMMENDINGEN/GERMANY · TEL. +49(0)7641-96256-0 · FAX +49(0)7641-96256-30

WWW.SUTTER-MED.COM · INFO@SUTTER-MED.DE