

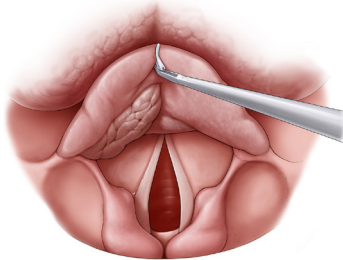
# Procedure Guidelines for Transoral Removal of Supraglottic Laryngeal Tumors Using Microelectrodes



## Indications and contraindications

The indications and contraindications for resections of supraglottic laryngeal tumors using ARROWtip™ monopolar microdissection electrodes correspond to those for the surgical removal of benign and malignant supraglottic tumors.

However, it is a prerequisite that the patient can be properly prepared for resection of the tumor with the micro-laryngoscope or distending laryngoscope. Tumors on the exposed edge of the epiglottis, central suprahoid epiglottic carcinomas, carcinomas at the edge of the false vocal cords, and carcinomas in the area of the aryepiglottic fold are especially well suited for this (Fig. 1).



Supraglottic carcinomas

## Patient preparation

General anesthesia is used. A local anesthetic (e.g. Ultracaine 1% Suprarenine) may be injected with a vasoconstrictor, depending on the surgeon's preferences.

Since monopolar electrodes are used, a neutral electrode is attached to the patient (e.g. right upper arm).

## Intervention

The surgical procedure begins with an operating laryngoscope (e.g. Kleinsasser micro-laryngoscope). The hand instruments still required are micro-forceps and a non-stick suction tube (REF 71 50 17) for hemostasis, which are also used in conventional laryngeal microsurgery.

The benefit of ARROWtip™ monopolar microdissection electrodes is that resection outside the line of sight is also possible thanks to the available angled models.

Smaller, defined epiglottic carcinomas (suprahoid) can be resected using an ARROWtip™ (straight or angled; REF 36 03 71 or REF 36 03 75) along the tumor with the required distance.

The depth extension of epiglottic carcinomas (infrahyoid) must be considered prior to the procedure. This is often difficult in the area of the petiole. The preepiglottic space may be infiltrated with such carcinomas. In this case the preepiglottic adipose body first has to be exposed after severing the vascular bundle in the pharyngoepiglottic fold with Calvian® bipolar forceps (REF 70 09 46). This is performed by means of medial transection of the glossoepiglottic fold with a straight ARROWtip™. In the next step, the epiglottis is transected with a straight ARROWtip™ monopolar microdissection electrode (Fig. 2). The epiglottis is pulled in the dorsal direction (towards the pharynx) using forceps during this step. This also allows the lingual surface to be seen. Following the caudal sagittal incision of the epiglottis, a horizontal lateral incision is made in the next step (Fig. 3) with a 90° angled ARROWtip™ monopolar microdissection electrode (REF 36 03 73).

A good view of the incision is important here in order to avoid injuries to other structures (cartilage, nerves, larger vessels). If areas of the thyroid or arytenoid cartilage are also infiltrated, they can be included in the resection. A temporary precautionary tracheotomy and feeding by stomach tube may be required. This needs to be decided on a case-by-case basis.

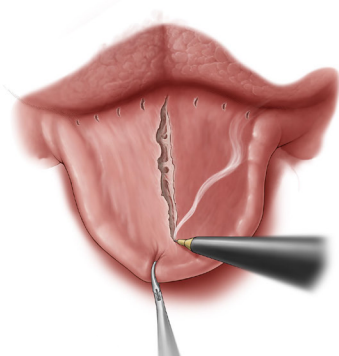


Fig. 2: Medial transection of the glossoepiglottic fold with a straight ARROWtip™ monopolar microdissection electrode (REF: 36 03 71).

## Postoperative treatment

The patient is discharged 1 to 5 days postoperatively depending on the extent of resection. A temporary precautionary tracheotomy should be performed for larger resections.

Partial or complete voice rest in the first few days is recommended. Logopedic exercises may already be indicated at this stage as well. Antitussives may be used to suppress a nervous cough and corticosteroids if there is a risk of edema. Postoperative treatment is similar to that of patients who undergo the CO<sub>2</sub> laser procedure.

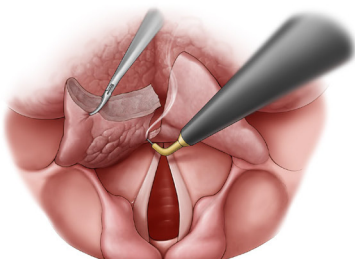
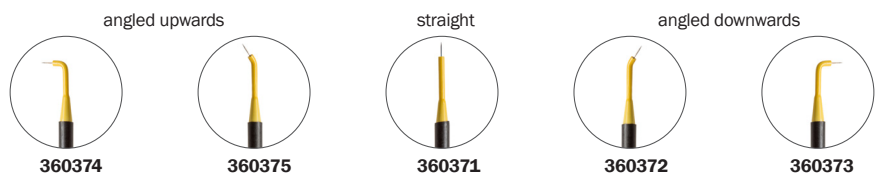
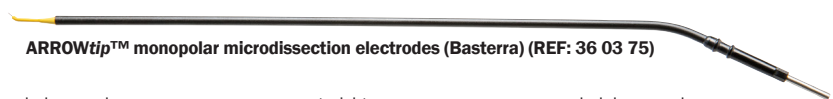

Fig. 3: Horizontal lateral incision with a 90° angled ARROWtip™ monopolar microdissection electrode (REF: 36 03 73).

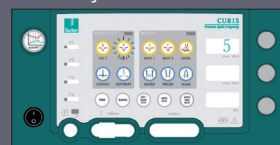

Settings\* for CURIS® 4 MHz radiofrequency generator (REF: 36 01 00-01)

Valid for the CURIS® with the orange label.



ARROWtip™: Monopolar CUT 2  
Power adjustment: 5 to 25 watts



**Other accessories:**  
Monopolar handpiece (REF: 36 07 04),  
Calvian® (with suction REF: 70 09 46; without suction REF: 70 09 47), cable (REF: 36 02 38),  
and single-use patient plate (REF: 36 02 22)

ARROWtip™: Monopolar CUT 2  
Power adjustment: 25 to 46 watts



**Other accessories:**  
Monopolar handpiece (REF: 36 07 04),  
Calvian® (with suction REF: 70 09 46; without suction REF: 70 09 47), cable (REF: 36 02 38),  
and single-use patient plate (REF: 36 02 22)

**Disclaimer:** These procedure guidelines have been carefully researched and compiled with the help of specialist physicians. They are not meant to serve as a detailed treatment guide. They do not replace the user instructions for the medical devices used. Sutter accepts no liability for the treatment results beyond legal regulations.

\* Please consider that this information is not meant to serve as a detailed treatment guide. Always start with the lowest settings and adjust them accordingly.