

Procedure Guidelines for Radiofrequency Rhinophyma Resection



Subject to change - REF: 12142A - R02 - Printed on chlorine-free, bleached paper © Copyright Sutter Medizintechnik GmbH · Tullastraße 87 · 79108 Freiburg/Germany · Tel. +49 (0)761 51551-0 · www.sutter-med.de

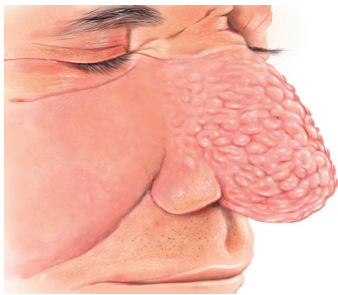


Fig. 1: Prior to rhinophyma resection

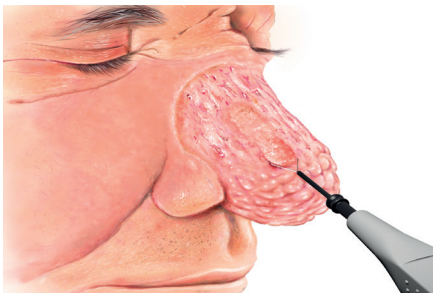


Fig. 2: During rhinophyma resection

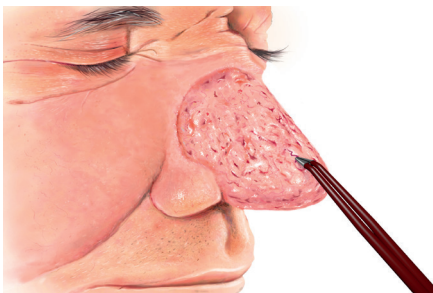


Fig. 3: Bipolar coagulation of remaining bleeders

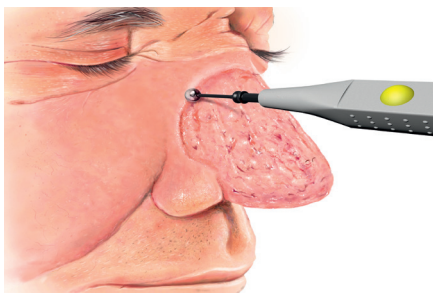


Fig. 4: Sculpting of nasal contours

Disclaimer: These procedure guidelines have been carefully researched and compiled with the help of specialist physicians. They are not meant to serve as a detailed treatment guide. They do not replace the user instructions for the medical devices used. Sutter accepts no liability for the treatment results beyond legal regulations.

Indications /Contraindications

Patients with late stage rosacea of the nose (rhinophyma) requiring treatment. Treatment may be indicated for patients with symptomatic problems or for esthetic reasons.

There are no contraindications for RF surgery. For patients with implanted pacemakers see instructions for use of the electrosurgical device employed.

Patient preparation

Apply an anesthetic ointment (e.g. EMLA cream) generously to the surface of the nose. After an exposure time of about 25 minutes administer a local anesthetic (e.g. injection of 15 ml prilocaine 1 % with epinephrine 1:200 000). Perioperative sedation (e.g. midazolam) of the patient is optional.

Examine the integrity and intactness of the electrodes employed prior to use.

Intervention

Determine the resection limits.

For large rhinophyma begin with the excision of large tissue masses using a needle electrode (REF 36 08 04). For smaller rhinophyma or after removal of larger tissue masses proceed with a triangle-shaped loop electrode (REF 36 08 12) and delaminate thin layers of tissue along the original shape of the nose.

Take great care not to excise further than down to the thin corium layer of the skin and not to damage the cartilage structure of the nose which could lead to cartilage necrosis. Finally sculpt the edges between the wound site and healthy skin area with a ball electrode (REF 36 08 17) at a low power setting. The temporary occurrence of a pale coagulation zone contributes to a smooth transition in the healing process of the skin.



Fig. 6: Loop electrode (REF: 36 08 12)



Fig. 7: Ball electrode (REF: 36 08 17)



Fig. 8: SuperGliss® non-stick bipolar forceps (REF: 78 01 75 SG)

Postoperative treatment

Generously apply an antibiotic, cortisone ointment (e.g. sulmycine with celestan V). Cover the nose with wound gauze such as paraffin gauze.

Settings* for CURIS® 4 MHz radiofrequency generator (REF: 36 01 00-01)

Valid for the CURIS® with the orange label.



Loop electrode: Monopolar CUT 2 or SOFTSPRAY
Power adjustment: 30 to 40 watts

Ball electrode: Monopolar CONTACT Coag
Power adjustment: 5 to 8 watts

SuperGliss® non-stick: Bipolar PRECISE
Power adjustment: 15 to 30 watts



Other accessories: Bipolar cable (REF: 37 01 54 L), monopolar handpiece (REF: 36 07 04), cable (REF: 36 02 38), and single-use patient plate (REF: 36 02 22)

Loop electrode: Monopolar CUT 2 or SOFTSPRAY
Power adjustment: 40 to 60 watts

Ball electrode: Monopolar CONTACT Coag
Power adjustment: 20 to 40 watts

SuperGliss® non-stick: Bipolar PRECISE
Power adjustment: 15 to 30 watts



Other accessories: Bipolar cable (REF: 37 01 54 L), monopolar handpiece (REF: 36 07 04), cable (REF: 36 02 38), and single-use patient plate (REF: 36 02 22)

* Please consider that this information is not meant to serve as a detailed treatment guide. Always start with the lowest settings and adjust them accordingly.