

Radiofrequency Surgery of an Oral Squamous Cell Carcinoma followed by Reconstruction with a Radial Forearm Flap

Timon Hussain, MD, Boris A. Stuck, MD, Department of Otorhinolaryngology, Head and Neck Surgery, University Hospital Essen, Germany

Radiofrequency (RF) surgery enables precise soft tissue resection while causing limited thermal damage. In this study, an advanced stage tongue tumor was successfully resected with RF surgery followed by reconstruction with a radial forearm flap.

Introduction: Surgery is the preferred treatment option for early stage and resectable advanced Oral Squamous Cell Carcinoma (OSCC) [1]. Particularly for tongue tumors, precise resection is crucial to ensure tumor-free surgical margins while preserving as much healthy tongue tissue as possible to retain functionality. Over the past years, transoral laser microsurgery has been established as a viable organ-preserving approach [2]; however, while facilitating precise resection, thermal tissue damage is a key limiting factor. Both the evaluation of surgical margins, as well as the integration of reconstructive flaps may be compromised [3]. By comparison, RF surgery induces lower temperatures, thereby causing less damage to surrounding tissues. While RF surgery has become increasingly popular for inferior turbinate, soft palate and base of tongue procedures ensuring precise local resection with low complication rates [4-6], its application for tumor resection has yet to be evaluated.

Materials and Methods: In this proof of concept study, we performed primary tumor resection of a T3 squamous cell carcinoma of the tongue (Fig. 1) with RF surgery with intraoperative frozen section evaluation. Bilateral

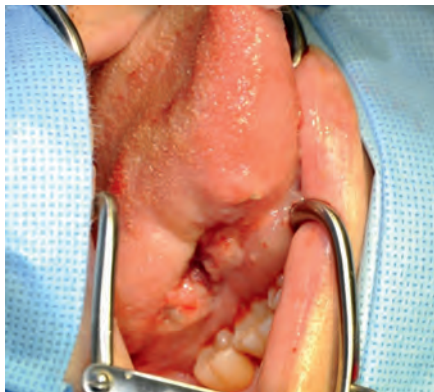

Fig. 1: Preoperative image of the large tongue tumor

teral neck dissection was performed prior to tumor resection. We used the BM-780 II radiofrequency generator with a straight ARROWtip™ monopolar microdissection electrode (long shaft, electrode diameter 0.3 mm) in the monopolar cutting mode (Sutter Medizintechnik, Freiburg/Germany). Pre-operative MRI showed a tumor extension of 41 x 16 mm. The large tumor could be precisely resected in one piece with the RF electrode, causing minimal bleeding and no

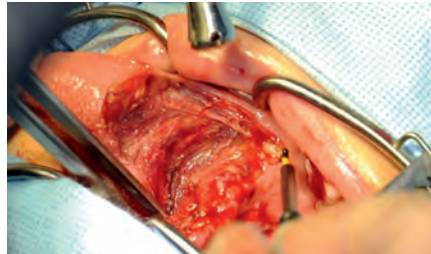


Fig. 2: Precise tumor resection with the monopolar RF electrode showing minimal visible thermal damage to surrounding tissues.

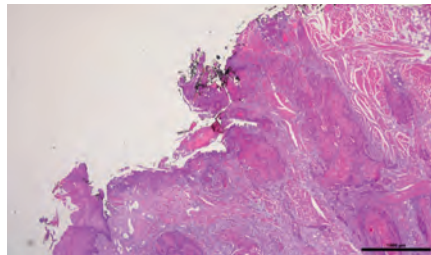


Fig. 3: Infiltrating tumor cells at the resection border are clearly visible, due to minimal thermal damage caused by RF.

visible thermal damage to the surrounding tissue (Fig. 2). After initial removal of the tumor, tissue samples were obtained from all resection borders. Intraoperative frozen section analysis showed tumor cells infiltrating margins (Fig 3), warranting further resection. Hereby, tumor-free surgical margins were achieved, allowing for ensuing tongue reconstruction with a radial forearm flap (Fig. 4).

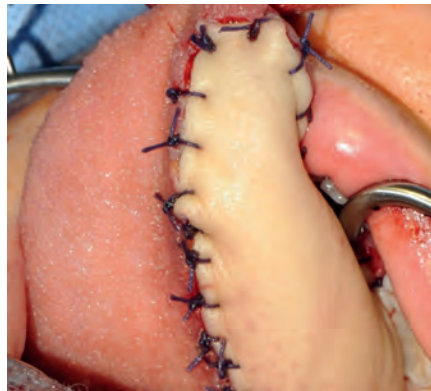


Fig 4: Tongue reconstruction with a radial forearm flap after tumor excision.

Results and Conclusions: In this single case study, RF surgery enabled accurate resection of an advanced tongue tumor. Importantly, limited thermal damage at the resection borders allowed for uncompromised intraoperative frozen section analysis revealing localized tumor remnants, ultimately leading to tumor-free (R0) resection

status after further selective resection. The RF device was easy to handle requiring no additional safety measures for study personnel. Notably, surgical precision was not compromised by intraoperative tongue movement. Intraoperative lingual muscle stimulation frequently occurs during conventional high-frequency surgery and is reduced with RF, as long as direct stimulation of the hypoglossal nerve can be avoided. Despite the large size of the tumor which required substantial resection, post-operative analysis showed limited tongue swelling and excellent local adaptation of the free flap.

In conclusion, our single case experience suggests that RF surgery is a promising technology for the resection of oral squamous cell carcinomas, particularly where maximum preservation of surrounding tissue is required.



Timon Hussain, MD Boris A. Stuck, MD
Department of Otorhinolaryngology, Head and Neck Surgery, University Hospital Duisburg-Essen, Germany

Correspondance: University Hospital Duisburg-Essen/Germany, Hufelandstraße 55, 45147 Essen, Tel.: +49 201/723-2481, E-Mail: timon.hussain@uk-essen.de

References: 1. Pfister DG, Ang KK, Brizel DM et al. Head and neck cancers. Journal of the National Comprehensive Cancer Network : JNCCN 2011; 9:596-650. 2. Sinha P, Hackman T, Nussenbaum B, Wu N, Lewis JS, Jr., Haughey BH. Transoral laser microsurgery for oral squamous cell carcinoma: oncologic outcomes and prognostic factors. Head & neck 2014; 36:340-351. 3. Buchanan MA, Coleman HG, Daley J et al. Relationship between CO laser-induced artifact and glottic cancer surgical margins at variable power doses. Head & neck 2015. 4. Blumen MB, Chalumeau F, Gauthier A, Bobin S, Coste A, Chabolle F. Comparative study of four radiofrequency generators for the treatment of snoring. Otolaryngology--head and neck surgery : official journal of American Academy of Otolaryngology-Head and Neck Surgery 2008; 138:294-299. 5. Back LJ, Liukko T, Sinkkonen ST, Ylikoski J, Makitie AA. Complication rates of radiofrequency surgery in the upper airways: a single institution experience. Acta otolaryngologica 2009; 129:1469-1473. 6. Bran GM, Hunnebeck S, Herr RM, Hormann K, Stuck BA. Bipolar radiofrequency volumetric tissue reduction of the inferior turbinates: evaluation of short-term efficacy in a prospective, randomized, single-blinded, placebo-controlled crossover trial. European archives of oto-rhino-laryngology : official journal of the European Federation of Oto-Rhino-Laryngological Societies 2013; 270:595-601.

Featured Products

Ø 0,3 mm



1:1



Qty.	REF	Description
2	36 03 40	ARROWtip™ monopolar microdissection electrode, straight, Ø 2.4 mm, total length 109 mm



86 00 10 – BM-780 II basic set with single-use patient plates

Qty.	REF	Description
1	36 00 80-01	BM-780 II radiofrequency generator (incl. mains cord, user manual, test protocol and instruction CD-ROM)
1	36 01 05	Footswitch, protection class, IP X8
1	37 01 38L	Bipolar silicone cable, length 4.5 m
1	36 02 18	Monopolar pencil for Ø 2.4 mm shaft electrodes, cable length 4 m
1	36 02 36	Cable for single-use patient plates, length 4.5 m
1 (x50)	36 02 22	Divided Premium single-use patient plate adhesive – electrically conductive, measurements: 176 x 122 mm, unit: 5 x 10 pcs.

Unit settings / Other accessories

BM-780 II radiofrequency generator
ARROWtip™ electrode: Monopolar CUT 1
 Power adjustment: 3-4



87 00 10 – CURIS® basic set with single-use patient plates

Qty.	REF	Description
1	36 01 00-01	CURIS® 4 MHz radiofrequency generator (incl. main cord, user's manual and test protocol)
1	36 01 10	Footswitch two pedals for CURIS® (cut & coag), 4 m cable
1	37 01 54L	Bipolar cable for CURIS®, length 3 m
1	36 07 04	Monopolar handpiece (pencil) cut & coag, shaft 2.4 mm, cable 3 m
1	36 02 38	Cable for single-use patient plates, length 3 m
1 (x50)	36 02 22	Safety patient plates, single-use, packing 5 x 10 pcs. (not shown)

Unit settings / Other accessories*

CURIS® 4 MHz radiofrequency generator
ARROWtip™ electrode: Monopolar CUT 1
 Power adjustment: 21-28 watts

CURIS® 4 MHz radiofrequency generator
ARROWtip™ electrode: Monopolar CUT 1
 Power adjustment: 20-50 watts

Valid for the **CURIS®** with the orange label.



* Please consider that this information is not meant to serve as a detailed treatment guide. Always adjust according to patient and application.



SUTTER MEDIZINTECHNIK GMBH

ALFRED-WALZ-STR. 22 · 79312 EMMENDINGEN/GERMANY · TEL. +49(0)7641-96256-0 · FAX +49(0)7641-96256-30

WWW.SUTTER-MED.COM · INFO@SUTTER-MED.DE