

Radiofrequency Surgery for Resection of a Cutaneous Angiosarcoma of the Face

Timon Hussain, MD, Boris A. Stuck, MD, Department of Otorhinolaryngology, Head and Neck Surgery, University Hospital Essen, Germany

Introduction: Angiosarcomas are rare cutaneous tumors, and presentations in the head and neck comprise the most common anatomic sites. For non-metastatic cutaneous angiosarcomas, combined multimodal therapy including surgical resection and radiation therapy has the best clinical outcome.^{1,2} Diagnosis is often delayed due to the benign appearance of the disease and excision of large tumors of the scalp and face can be challenging. Precise resection with clear surgical margins is required to ensure regional control while preserving crucial anatomical structures. We demonstrate the use of RF surgery in the case of an 80-year old male patient presenting with a stage IIB angiosarcoma located medial to the left eye with invasion of the upper and lower eye lid.

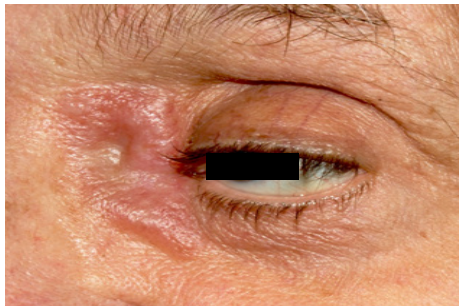


Fig 1: Pre-operative image of the angiosarcoma involving the upper and lower eye lid.

in the monopolar cutting mode (Sutter® Medizintechnik, Freiburg/ Germany). The tumor could be precisely resected with the RF electrode, causing limited bleeding and minimal damage to immediately adjacent orbital structures.

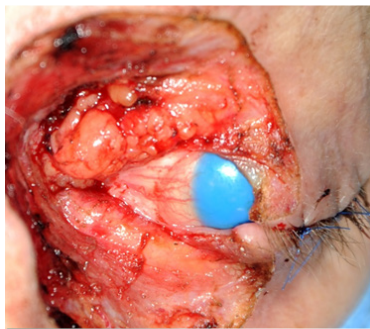


Fig 2: Intraoperative image after tumor resection with the RF device showing minimal thermal tissue damage.

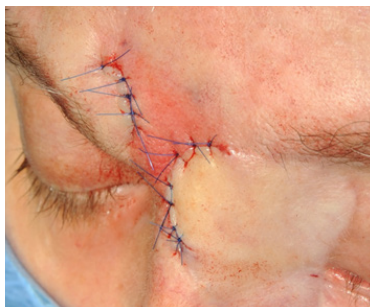

Fig 3: Reconstruction of the large tissue defect with a forehead flap; image acquired after pedicle division.

Methods:

We performed primary tumor resection with RF surgery with intraoperative frozen section evaluation. The RF generator BM-780 II was used with an ARROWtip™ microdissection needle (long shaft diameter 0.3 mm) in

Tissue samples were obtained from all resection borders showing clear surgical margins. In a second procedure, reconstruction of the tissue defect was performed using a pedicled paramedian forehead flap; pedicle division was performed three weeks after reconstruction. Hereby, good aesthetic and functional outcomes were achieved and post-operative ophthalmologic assessment showed no loss in eye movement.

Discussion: Currently, RF surgery is most commonly used in turbinate, soft palate and base of tongue procedures with low reported complication rates and favorable functional outcomes³⁻⁵. Here, we show its successful application for the resection of a large malignant facial lesion. Compared to “coldsteel” re-

section, RF technology causes reduced intraoperative bleeding while also inducing less thermal damage to surrounding tissues than standard monopolar resection. Pressure-free resection with the RF electrode proved to be particularly beneficial within the soft facial tissues, enabling highly precise resection. For surgical resection with a scalpel, pressure application and traction are required. In the presented case, orbital structures could be preserved despite their immediate proximity to the tumor. A pedicled forehead flap was used for reconstruction. Pedicled flaps are generally robust thanks to reliable perfusion, and the forehead flap provides sufficient volume to cover large tissue defects with favorable aesthetic results.⁶ Post-operative follow-up showed excellent flap vascularization after pedicle division and good aesthetic outcome.

In conclusion, the presented case suggests that RF surgery is a promising technology with easy handling and high device security for the resection of facial lesions. Postoperative functional and aesthetic outcomes were encouraging.



ARROWtip™, microdissection needle, 0.3 mm (REF: 360321)



Dr. med. Timon Hussain
University Hospital Essen, Germany



Prof. Dr. Boris A. Stuck
University Hospital Essen, Germany

Correspondence: Dr. Timon Hussain, Dr. Boris A. Stuck,

References: 1. Guadagnolo BA, Zagars GK, Araujo D, Ravi V, Shellenberger TD, Sturgis EM. Outcomes after definitive treatment for cutaneous angiosarcoma of the face and scalp. *Head & Neck* 2011; 33:661-667. 2. Patel SH, Hayden RE, Hinni ML et al. Angiosarcoma of the scalp and face: the Mayo Clinic experience. *JAMA Otolaryngology- Head & Neck Surgery* 2015; 141:335-340. 3. Blumen MB, Chalumeau F, Gauthier A, Bobin S, Coste A, Chabolle F. Comparative study of four radiofrequency generators for the treatment of snoring. *Otolaryngology-Head and Neck Surgery : Official Journal of American Academy of Otolaryngology-Head and Neck Surgery* 2008; 138:294-299. 4. Back LJ, Liukko T, Sinkkonen ST, Ylikoski J, Makitie AA. Complication rates of radiofrequency surgery in the upper airways: a single institution experience. *Acta Oto-Laryngologica* 2009; 129:1469-1473. 5. Bran GM, Hunnebeck S, Herr RM, Hormann K, Stuck BA. Bipolar radiofrequency volumetric tissue reduction of the inferior turbinates: evaluation of short-term efficacy in a prospective, randomized, single-blinded, placebo-controlled crossover trial. *European Archives of Oto-Rhino-Laryngology : official Journal of the European Federation of Oto-Rhino-Laryngological Societies* 2013; 270:595-601. 6. Pawar SS, Kim MM. Updates in forehead flap reconstruction of facial defects. *Current opinion in otolaryngology & head and neck surgery* 2013; 21:384-388.

Tel.: +49 (0)7641 962560
info@sutter-med.de • www.sutter-med.de



Featured Product

360321 – ARROWtip™ electrode

Qty.	REF	Description
1	360321	ARROWtip™ electrode, Ø 0,3 mm, total length 53 mm

Ø 0,3 mm



1:1



860010 – BM-780 II basic set with single-use patient plates

Qty.	REF	Description	Unit settings / Other accessories
1	360080-01	Radiofrequency-Generator BM-780 II (incl. mains cord, user manual, test protocol and instruction CD-ROM)	BM-780 II
1	360105	Footswitch, protection class, IP X8	ARROWtip™ electrode : Monopolar CUT 1
1	370138L	Bipolar silicone cable, length 4,5 m	Power adjustment: 3-4
1	360218	Monopolar pencil for Ø 2.4 mm shaft electrodes, cable length 4 m	
1	360236	Cable for single-use patient plates, length 4,5 m	
1 (x50)	360222	Divided Premium single-use patient plate adhesive – electrically conductive, measurements: 176 x 122 mm, unit: 5 x 10 pcs.	



SUTTER MEDIZINTECHNIK GMBH

ALFRED-WALZ-STR. 22 · 79312 EMMENDINGEN / GERMANY · TEL. +49 (0)7641 96256-0 · FAX +49 (0)7641 96256-30

WWW.SUTTER-MED.COM · WWW.SUTTER-MED.DE · E-MAIL : INFO@SUTTER-MED.DE