

Radiofrequency Surgery Spares Tissue and Improves Operation Comfort in Skin Surgery

By Robert Kasten, MD, Mainz/Germany

Fast wound healing and good cosmetic results are of great importance in skin surgery. Radiofrequency surgery causes less lateral tissue damage than conventional electrosurgery. Consequently faster wound healing and a better cosmetic outcome can be expected. Studies have even shown better cosmetic results for radiofrequency skin surgery than for CO₂ laser applications. Radiofrequency also improves operation comfort by enabling germ-free and pressure-free cuts with minimal bleeding in a very cost effective way. We present a short review of the literature and our own histopathological findings.

Introduction: Radiofrequency (4 MHz) surgery is an established procedure in skin surgery that allows the cutting of tissue with minimal bleeding and the least thermal damage. Besides a dry surgical field, another advantage of the RF cut over "cold steel" cuts is the freedom of movement that can be achieved with a small needle or blade electrode [1].

Histopathology: In an exemplary case of neurofibromatosis type I, we had specimens examined histopathologically. We excised the tumor under local anaesthesia with a short-angled ARROWtip needle electrode (REF 360321, Sutter) attached to a 4 MHz radiofrequency unit ("CURIS" RF generator, Sutter). The neurofibroma was excised to the subcutaneous plane with the CURIS® set to 7 watts in a pure cutting mode. The defect was closed with absorbable, subcutaneous sutures and cutaneous interrupted sutures. The non-absorbable suture material was removed on the seventh day postoperatively.

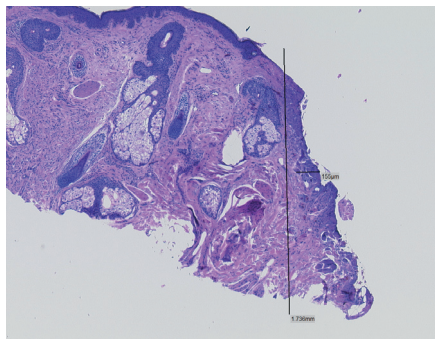


Figure 1: Lateral thermal damage during radiofrequency excision: 155µm

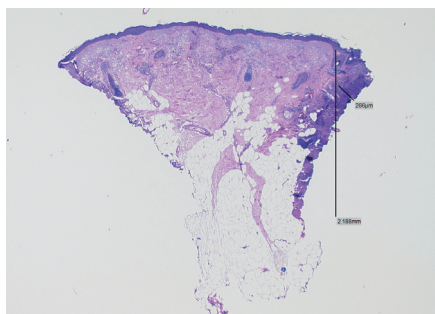


Figure 2: Lateral thermal damage during conventional electrosurgery excision: 286µm

Results: Wound healing was uneventful. Histologic examination showed a lateral thermal damage of 150 micrometer caused by the radiofrequency unit CURIS® (Fig. 1). The depth of the incised skin measured over 1.7 mm. On the same specimen a cut was made with a conventional electrosurgical unit (Berchtold Elektrotom 400), operating at 500 kHz, using the same electrode at comparable power. Histopathology showed a necrosis of approx. 286 µ – almost twice the thermal damage that occurred during the use of the CURIS® (Fig. 2).



Figure 3: Monopolar ARROWtip electrode, short-angled

Discussion: In a study on excisions of thin upper eyelid skin, radiofrequency was superior to the CO₂ laser method [1]. For incisions in thicker facial skin such as the forehead, higher power settings are required that will increase lateral thermal damage as a result. Nevertheless, surgery with the radiofrequency unit CURIS® yielded good cosmetic results.

Conventional electrocautery machines work at frequencies between 350 and 500 kHz and cause greater lateral thermal damage than the CURIS® that cuts with a tissue-gentle power output of 4 MHz. Bridenstine [2] even speaks of a thermal damage margin of 75 µm when using radiofrequency for skin cuts, but fails to indicate the depth of the skin incision. Pollack [3] reports faster initial reepithelialization with cold steel cuts, but also shows similar results at the end of the healing period. Hambley [4] established that even conventional electrosurgery creates less epidermal destruction than the CO₂ laser. Our findings and those of others [5] show the RF cut to be superior to cuts with conventional electrosurgery, which operates at lower frequencies.



Figure 4: CURIS® radiofrequency unit (Sutter/Germany)

Conclusion: Radiofrequency surgery is an important tool for skin surgeons. It is an innovative method that allows the excision of benign tumors, even in the deeper layers of the skin, with good cosmetic results. Radiofrequency offers the advantages of germ-free and pressure-free cuts with minimal bleeding in a very cost effective way. Radiofrequency certainly enriches our surgical armamentarium.



Robert Kasten, MD
Board certified Dermatologist
Mainz/Germany

Correspondence: Dr. Robert Kasten, MD, Dermatologic Surgery, Martinsstr. 17, 55116 Mainz, Germany, Tel. +49 6131 9727920, E-Mail: rkasten@web.de

References: 1. Welch DB, Bryar P; Two year follow up: Radiosurgery better than laser; Ocular Surgery News; Vol 20 (12), June 2002 2. Bridenstine, James B.; Use of Ultra-High Frequency Electrosurgery (Radiosurgery) for Cosmetic Surgical Procedures; Dermatological Surgery, Vol 24, 1998; 397-400 3. Pollack, Sheldon V., et al; Comparative Study of Wound Healing in Porcine Skin with CO₂ Laser and Other Surgical Modalities: Preliminary Findings; Int-Otern. J. of Dermatology, Vol 34 (1), 1995; 42-47 4. Hambley, R. et al; Wound Healing of Skin Incisions Produced by Ultrasonically Vibrating Knife, Scalpel, Electrosurgery, and Carbon Dioxide Laser; Dermatological Surgery Oncology, V 14, 1988; 1213-217 5. Maness, W. L. et al; Histologic evaluation of electrosurgery with varying frequency and waveform; J Prosthetic Dentistry, 1978



SUTTER MEDIZINTECHNIK GMBH

TULLASTRASSE 87 · 79108 FREIBURG / GERMANY · TEL. +49 (0)761 51551-0 · FAX +49 (0)761 51551-30
WWW.SUTTER-MED.COM · WWW.SUTTER-MED.DE · E-MAIL: INFO@SUTTER-MED.DE